

A PRELIMINARY OVERVIEW OF SKIN AND SKELETAL DISEASES AND TRAUMATA IN SMALL CETACEANS FROM SOUTH AMERICAN WATERS

MARIE-FRANÇOISE VAN BRESSEM^{1,*}, KOEN VAN WAEREBEEK¹, JULIO C. REYES², FERNANDO FÉLIX³, MÓNICA ECHEGARAY², SALVATORE SICILIANO⁴, ANA PAULA DI BENEDITTO⁵, LEONARDO FLACH⁶, FRANCISCO VIDDÍ⁷, ISABEL CRISTINA AVILA⁸, JULIO CÉSAR HERRERA⁹, ISABEL CRISTINA TOBÓN⁹, JAIME BOLAÑOS-JIMÉNEZ¹⁰, IGNACIO B. MORENO¹¹, PAULO H. OTT^{11,12}, GIAN PAOLO SANINO¹³, ELENA CASTINEIRA¹⁴, DAVID MONTES¹, ENRIQUE CRESPO¹⁵, PAULO A.C. FLORES¹⁶, BEN HAASE³, SHEILA M. F. MENDONÇA DE SOUZA⁴, MAÍRA LAETA⁴ AND ANA BERNADETE FRAGOSO¹⁷

ABSTRACT: We succinctly review and document new cases of diseases of the skin and the skeletal system and external traumata in cetaceans from Ecuador, Colombia, Peru, Chile, Argentina, Uruguay, Brazil, and Venezuela. The survey revealed 590 cases diagnosed with a significant pathology, injury or malformation on a total of 7635 specimens of 12 odontocete species examined or observed in 1984-2007. Tattoo skin disease (TSD), lobomycosis-like disease (LLD) and cutaneous diseases of unknown aetiology seem to be emerging in several populations. TSD was confirmed in eight species from the SE Pacific and SW Atlantic. LLD affected only inshore *Tursiops truncatus* but was found in four tropical countries, namely Colombia, Ecuador, Peru and Brazil. Lobomycosis was confirmed by histology in one male from the Tramandai estuary, southern Brazil. All LLD-affected specimens were encountered in the vicinity of major ports and cities and a possible association with chemical or organic water pollution is suspected. Whitish velvety cutaneous marks associated with scars occurred in inshore *T. truncatus*, *Sotalia guianensis* and *Pseudorca crassidens*. Large, rounded lesions were seen in a *Cephalorhynchus eutropia* calf and a *C. commersonii*. Cutaneous wounds and scars as well as body traumata possibly related to net entanglements and boat collisions were observed in 73 delphinids and *Phocoena spinipinnis*. Traumatic injuries resulted in the partial or complete amputation and other disfiguring scars of appendages in 17 cases. Fractures of the skull, ribs and vertebrae thought to be caused by fisheries-related interactions or boat collisions were seen in single individuals of *Delphinus capensis*, *Lagenorhynchus obscurus*, *T. truncatus*, *S. guianensis* and *Ziphius cavirostris*. Prevalence of osteopathology in small cetaceans from Peru, Brazil and Venezuela ranged widely, from 5.4% to 69.1%. In four species from Peru, lytic cranial lesions were the most frequently observed disease (5.4%-42.9%), followed by hyperostosis and ankylosing spondylitis in offshore (31%, n=42) and inshore (15.4%, n=26) *T. truncatus*. Fractures and other bone traumata were present in 47.2% of 53 axial skeletons of *S. guianensis* from the northern Rio de Janeiro state (Brazil) in 1987-1998. A high prevalence (48.4%, n=31) of, apparently congenital, malformations of cervical vertebrae, observed in a 2001-2006 sample, may be explained by a hypothetical genetic bottleneck in this population. Malformations with deficient ossification would clearly increase susceptibility for fractures. This study demonstrates the utility of a continent-wide analysis to discern epizootiological trends more readily than any local study could provide. Secondly, it underscores the need for focussed research on the effects of human activities on the spread of diseases in cetaceans, particularly in near-shore populations that utilize highly degraded coastal habitats.

RESUMEN: En este trabajo revisamos y documentamos brevemente nuevos casos de enfermedades de piel y de esqueleto, y traumas externos en cetáceos de Ecuador, Colombia, Perú, Chile, Argentina, Uruguay, Brasil y Venezuela. De un total de 7635 especímenes de 12 especies de odontocetos examinados entre 1984 y 2007, se encontraron 590 casos con una patología significativa, heridas o malformaciones. Las condiciones conocidas como ‘enfermedad cutánea de tatuaje’ (TSD), ‘enfermedad

¹ Cetacean Conservation Medicine Group (CMED-CEPEC), Museo de Delfines, Pucusana, Peru.

* Corresponding author, e-mails: marievanbressem@yahoo.co.uk and mfb.cmed@gmail.com.

² Áreas Costeras y Recursos Marinos (ACOREMA). Av. San Martín 1471, Pisco, Peru.

³ Fundación Ecuatoriana para el Estudio de Mamíferos Marinos (FEMM). PO Box 09-01-11905, Guayaquil, Ecuador.

⁴ Grupo de Estudos de Mamíferos Marinhos da Região dos Lagos (GEMM-Lagos) & Laboratório de Ecologia, Departamento de Endemias Samuel Pessoa, Escola Nacional de Saúde Pública/FIOCRUZ. Rua Leopoldo Bulhões, 1480-térreo, Manginhos, Rio de Janeiro, RJ 21041-210 Brazil.

⁵ Universidade Estadual do Norte Fluminense-CBB, Laboratório de Ciências Ambientais. Av. A. Lamego, 2000, Campos dos Goytacazes, RJ 28013-602 Brazil.

⁶ Projeto Boto Cinza - MBR - Um Grupo CAEMI. Rua Sta Terezinha, 531 - 90 Vila Muriqui, Mangaratiba, RJ 23860-000 Brazil.

⁷ Marine Mammal Research Group, Graduate School of the Environment, Macquarie University, NSW 2109 Sydney, Australia and Centro Ballena Azul, Valdivia, Chile.

⁸ Universidad del Valle, Departamento de Biología, Grupo de Investigación en Ecología Animal, Cali, Colombia.

⁹ Fundación Yubarta. Carrera 24 F Oeste No. 3-110, Tejares De San Fernando, Cali (Valle), Colombia.

¹⁰ Sociedad Ecológica Venezolana Vida Marina (Sea Vida). A.P. 162, Cagua, Estado Aragua, Venezuela 2122.

¹¹ Grupo de Estudos de Mamíferos Aquáticos do Rio Grande do Sul (GEMARS) & Centro de Estudos Costeiros, Limnológicos e Marinhos da Universidade Federal do Rio Grande do Sul (CECLIMAR/UFRGS). Rua Felipe Néri, 382/203, Porto Alegre, RS 90440-150 Brazil.

¹² Universidade Estadual do Rio Grande do Sul (UERGS). Cidreira, RS, Brazil.

¹³ Centre for Marine Mammals Research LEVIATHAN. 7640392 Chile.

¹⁴ Facultad de Ciencias, Universidad de la República. Montevideo, Uruguay.

¹⁵ Centro Nacional Patagónico (CONICET). Boulevard Brown 3600, 9120 Puerto Madryn, Chubut, Argentina.

¹⁶ Centro Mamíferos Aquáticos (CMA) & Núcleo de Unidades de Conservação (NUC), Instituto CM de Conservação da Biodiversidade (Icmbio) & Ibama. R. Min. João G. de Souza, s/n, Dist. Industrial, Manaus, AM 69075-830 Brazil, and Instituto de Pesquisa e Conservação de Golfinhos, Florianópolis, SC Brazil.

¹⁷ Projeto Maqua - UERJ, Maracanã, Rio de Janeiro, RJ 20000-000 Brazil.

parecida a lobomycosis' (LLD) y enfermedades cutáneas de etiología desconocida parecen estar emergiendo en varias poblaciones de cetáceos. La presencia de TSD fue confirmada en ocho especies del Pacífico Sureste y del Atlántico Suroeste. LLD se encontró solamente en *Tursiops truncatus* costeros en cuatro países tropicales: Colombia, Ecuador, Perú y Brasil. Un caso de lobomycosis fue confirmado por histología en un macho de *T. truncatus* del estuario de Tramandaí en el sur de Brasil. Todos los especímenes con LLD fueron encontrados en la proximidad de puertos grandes y ciudades, y se sospecha una asociación con la contaminación química u orgánica del agua. En *T. truncatus* costeros, *Sotalia guianensis* y *Pseudorca crassidens* se observaron lesiones cutáneas blanquecinas y aterciopeladas asociadas con cicatrices. Grandes lesiones redondas fueron vistas en una cría de *Cephalorhynchus eutropia* y en un ejemplar de *C. commersonii*. Heridas cutáneas y cicatrices, así como traumas corporales, posiblemente relacionados con la captura en redes de pesca y colisiones con botes fueron registradas en 73 delfines y en *Phocoena spinipinnis*. Algunos traumas provocaron desde cicatrices desfigurantes hasta la amputación total o parcial de las aletas o de la cola de 17 especímenes. Fracturas del cráneo, de las costillas y de las vértebras, posiblemente causadas por interacciones violentas con pesquerías o colisiones con botes fueron observadas en individuos de *Delphinus capensis*, *Lagenorhynchus obscurus*, *T. truncatus*, *S. guianensis* y *Ziphius cavirostris*. La prevalencia de patologías óseas en pequeños cetáceos de Brasil, Perú y Venezuela osciló ampliamente entre 5.4% y 69.1% del total de los animales analizados. Las lesiones líticas del cráneo en *L. obscurus*, *D. capensis*, *T. truncatus* y *P. spinipinnis* del Perú constituyeron las enfermedades más frecuentemente observadas (5.4%- 42.9%), seguidas por hiperostosis y espondilitis anquilosante en *T. truncatus* oceánicos (31%, n=42) y costeros (15.4%, n=26). Fracturas y otros traumas óseos fueron registrados en el 47.2% de 53 esqueletos de *S. guianensis* en el norte del estado de Rio de Janeiro (Brasil) entre 1987 y 1998. La alta prevalencia de malformaciones, probablemente congénitas de las vértebras cervicales en una muestra colectada entre los años 2001 y 2006, puede ser debida a una situación de cuello de botella genético en esta población. Las malformaciones con déficit de osificación aumentarían claramente la predisposición a las fracturas. Este estudio demuestra la importancia de un análisis a escala regional, ya que en éste se disciernen las tendencias epizootológicas más fácilmente que en investigaciones a nivel local. Además indica la necesidad de una investigación dedicada a estudiar los efectos que tienen las actividades humanas en la diseminación de las enfermedades en cetáceos, especialmente en las poblaciones costeras que viven en un ambiente altamente deteriorado.

KEYWORDS: Cetaceans, diseases, skin, skeleton, traumata, malformations, epidemiology, South America, pollution.

Introduction

More than half (57.7%) of the 71 recognized odontocete species of the world inhabit the extensive marine and freshwaters of South America. There, as in many other areas, they face a host of human-caused threats including incidental mortality in fisheries, direct exploitation, vessel strikes as well as habitat degradation and loss, and a significant number of populations are considered vulnerable. Especially for the latter, any source of enhanced natural or anthropogenic mortality or morbidity should be of concern.

Although dedicated research on the epizootiology of infectious diseases is still in an early phase in South American (SA) cetaceans, a number of viruses, bacteria and disease-causing macroparasites have been documented in several species (see Table 1). Some have the potential for significant adverse impacts on population abundance by increasing baseline natural mortality (*e.g.* cetacean morbilliviruses, *Crassicauda* spp.

nematodes and, possibly, cetacean poxviruses) or by negatively affecting reproduction (*e.g.* *Brucella* spp., *Phocoena spinipinnis* papillomavirus type 1) (Van Bresseem and Van Waerebeek, 1996; Van Bresseem *et al.*, 1996; 1998; 1999; 2001a,b; 2006a; 2007a,b). *Brucella* spp. and cetacean poxviruses possibly represent a zoonotic threat (Van Bresseem *et al.*, 1993; 2001a; 2007b). Miscellaneous non-infectious diseases, lesions, anomalies and traumata are also commonly found in SA small cetaceans (*e.g.* Van Bresseem *et al.*, 2000; 2006b; Ramos *et al.*, 2001; Sánchez *et al.*, 2002; Flores *et al.*, 2005¹⁸; Flach, 2006¹⁹; Laeta *et al.*, 2006²⁰; Mendonça de Souza *et al.*, 2006²¹) and may also have a negative impact on reproductive success, impair feeding or cause premature death (Van Bresseem *et al.*, 2000; 2006b; Ramos *et al.*, 2001; Sánchez *et al.*, 2002; Siciliano *et al.*, in press). Anthropogenic activities may influence the course of diseases as well as directly cause traumata and lesions (Van Bresseem *et al.*, 1994; 1999; 2001b; Ross, 2002; Viddi *et al.*, 2005²²; Flach, 2006¹⁹).

¹⁸ Flores, P.A.C., Bazzalo, M., Da Silva, L.Z. and Wells, R.S. (2005) *Evidência de residência individual e ocorrência de lesões epidérmicas em golfinhos Tursiops truncatus na Baía Norte, SC, Brasil* Page 87 in: Abstracts, III Congresso Brasileiro de Mastozoologia, 12-16 October, 2005, Aracruz, ES, Brazil.

¹⁹ Flach, L. (2006) *Photo-identification study reveals human threats towards estuarine dolphins in southeast Brazil*. Page 46 in: Siciliano, S., Borobia, M., Barros, N.B., Marques, F.C., Trujillo, T. and Flores, P.A.C. (Eds) Workshop on Research and Conservation of the Genus *Sotalia*, 19-23 June 2006, Armação dos Búzios, RJ, Brazil.

²⁰ Laeta, M., Mendonça de Souza, S.M.F. and Siciliano, S. (2006) *Anomalias congênitas em Sotalia guianensis da costa norte da estado do Rio de Janeiro- Brasil*. Page 123 in Abstracts, I Congresso Sul-Americano de Mastozoologia, 5-8 October 2006, Gramado, RS, Brazil.

²¹ Mendonça de Souza, S.M.F., Laeta, M., and Siciliano, S. (2006) *Lesões ósseas em colunas vertebrais de golfinhos do gênero Sotalia, provenientes do litoral norte do Rio de Janeiro, Brasil*. Page 32 in Siciliano, S., Borobia, M., Barros, N.B., Marques, F.C., Trujillo, F., Flores, P.A.C. (Eds) Workshop on Research and Conservation of the Genus *Sotalia*, 19-23 June 2006, Armação dos Búzios, RJ, Brazil.

²² Viddi, F.A., Van Bresseem, M.-F., Bello, M. and Lescauwae, A.K. (2005) *First records of skin lesions in coastal dolphins off southern Chile*. 16th Biennial Conference on the Biology of Marine Mammals, 12-16 December 2005, San Diego, CA, USA.

Table 1. Overview of known infectious and non-infectious diseases of odontocetes from South American waters.

SPECIES	COUNTRY, AREA	DISEASE, PATHOANATOMICAL DIAGNOSIS OR SYMPTOMATOLOGY	SUSPECTED RELATED ENVIRONMENTAL FACTORS	SOURCE
<i>Cephalorhynchus eutropia</i>	Chile, N Patagonia	Rounded large cutaneous marks	Aquaculture	Viddi <i>et al.</i> (2005) ²² ; this paper
<i>Cephalorhynchus eutropia</i>	Chile, N Patagonia	Tattoo skin disease	Aquaculture	Viddi <i>et al.</i> (2005) ²² ; this paper
<i>Cephalorhynchus commersonii</i>	Argentina, Patagonia	Rounded large cutaneous marks		E. Crespo, M. Frixione and M.J. Klaich (personal observations); this paper
<i>Cephalorhynchus commersonii</i>	Argentina, Patagonia	Tattoo skin disease		E. Crespo and M.J. Klaich (personal observations); this paper
<i>Delphinus capensis</i>	Brazil, Araruama	Diffuse skeletal hyperostosis		Siciliano <i>et al.</i> (2005) ²⁵
<i>Delphinus capensis</i>	Peru, central coast	Tattoo skin disease- poxvirus infection		Van Bresseem and Van Waerebeek (1996); Van Bresseem <i>et al.</i> (2006a)
<i>Delphinus capensis</i>	Peru, central coast	Miscellaneous cutaneous lesions		Van Bresseem <i>et al.</i> (2006b)
<i>Delphinus capensis</i>	Peru, central coast	Skin discoloration		Van Bresseem <i>et al.</i> (2006b)
<i>Delphinus capensis</i>	Peru, central coast	Cutaneous scars	Fishery interactions	Van Bresseem <i>et al.</i> (2006b)
<i>Delphinus capensis</i>	Peru, central coast	Genital warts		Van Bresseem <i>et al.</i> (1996)
<i>Delphinus capensis</i>	Peru, central coast	Genital diseases		Van Bresseem <i>et al.</i> (2006b)
<i>Delphinus capensis</i>	Peru, central coast	Cetacean morbillivirus infection		Van Bresseem <i>et al.</i> (1998)
<i>Delphinus capensis</i>	Peru, central coast	<i>Brucella</i> spp. infection		Van Bresseem <i>et al.</i> (2001a)
<i>Delphinus capensis</i>	Peru, entire coast	Skull lesions, fractures and malformations	Fishery interactions (for some cases)	Van Bresseem <i>et al.</i> (2006b)
<i>Delphinus capensis</i>	Peru, entire coast	Dental and periodontal diseases		Van Bresseem <i>et al.</i> (2006b)
<i>Delphinus capensis</i>	Peru, northern and central coast	Lesions of the head, trunk and appendages	Fishery interactions	Van Bresseem <i>et al.</i> (2006b)
<i>Delphinus delphis</i>	Chile, Punta de Choros	Bacterial pneumonia		Samino <i>et al.</i> (2003)
<i>Delphinus delphis</i>	Ecuador	Tattoo skin disease		This paper
<i>Delphinus delphis</i>	Ecuador, Guayas	Ankylosing spondylitis (vertebrae)		M.P. Amador and W.E. Aguirre (unpublished data); this paper
<i>Feresa attenuata</i>	Peru, central and southern coast	Skull lesions		Montes-Iturrizaga (2003)
<i>Globicephala melas</i>	Peru, southern coast	Dental and periodontal diseases		Montes <i>et al.</i> (2004)
<i>Globicephala macrohynchus</i>	Peru, central coast	Dental and periodontal diseases		Montes <i>et al.</i> (2004)
<i>Globicephala macrohynchus</i>	Peru, central coast	Skull lesions and fractures		Montes <i>et al.</i> (2004)

continued

continued

SPECIES	COUNTRY, AREA	DISEASE, PATHOANATOMICAL DIAGNOSIS OR SYMPTOMATOLOGY	SUSPECTED RELATED ENVIRONMENTAL FACTORS	SOURCE
<i>Grampus griseus</i>	Peru, southern coast	Skull lesions		Montes <i>et al.</i> (2004)
<i>Lagenorhynchus australis</i>	Chile, N Patagonia	Deep wounds	Fishery interactions	F. Viddi (personal observations); this paper
<i>Lagenodelphis hosei</i>	Brazil, Arraial do Cabo	Cetacean morbillivirus infection		Van Bressem <i>et al.</i> (2001b)
<i>Lagenorhynchus obscurus</i>	Peru, central coast	Tattoo skin disease- poxvirus infection		Van Bressem and Van Waerebeek (1996); Van Bressem <i>et al.</i> (2006a)
<i>Lagenorhynchus obscurus</i>	Peru, central coast	Herpesvirus skin infection		Van Bressem <i>et al.</i> (1994)
<i>Lagenorhynchus obscurus</i>	Peru, central coast	Genital papillomas- papillomavirus infection		Van Bressem <i>et al.</i> (1996); Cassonnet <i>et al.</i> (1998)
<i>Lagenorhynchus obscurus</i>	Peru, central coast	Genital diseases		Van Bressem <i>et al.</i> (2000)
<i>Lagenorhynchus obscurus</i>	Peru, central coast	Cetacean morbillivirus infection		Van Bressem <i>et al.</i> (1998)
<i>Lagenorhynchus obscurus</i>	Peru, central coast	<i>Brucella</i> spp. infection		Van Bressem <i>et al.</i> (2001a)
<i>Lagenorhynchus obscurus</i>	Peru, central and southern Peru	Skull lesions, fractures and malformations	Fishery interactions (for some cases)	Montes <i>et al.</i> (2004); this paper
<i>Lagenorhynchus obscurus</i>	Peru, central coast	Dental and periodontal diseases		Montes <i>et al.</i> (2004); this paper
<i>Mesoplodon peruvianus</i>	Peru, southern coast	Skull lesions		Montes-Iturrizaga (2003)
<i>Orcinus orca</i>	Brazil, Rio de Janeiro	Osteochondromatosis		Siciliano <i>et al.</i> (in press)
<i>Phocoena spinipinnis</i>	Peru, central coast	Cetacean morbillivirus infection		Van Bressem <i>et al.</i> (1998)
<i>Phocoena spinipinnis</i>	Peru, central coast	Tattoo skin disease-poxvirus infection		Van Bressem and Van Waerebeek (1996); Van Bressem <i>et al.</i> (2006a)
<i>Phocoena spinipinnis</i>	Peru, central coast	Genital warts- papillomavirus infection		Van Bressem <i>et al.</i> (1996); Van Bressem <i>et al.</i> (2007a)
<i>Phocoena spinipinnis</i>	Peru, central coast	<i>Brucella</i> spp. infection		Van Bressem <i>et al.</i> (2001a)
<i>Phocoena spinipinnis</i>	Peru, northern coast	Dental and periodontal diseases		Montes <i>et al.</i> (2004); this paper
<i>Phocoena spinipinnis</i>	Peru, central coast	Osteolysis and osteomyelitis (skull)		Montes <i>et al.</i> (2004); this paper
<i>Phocoena spinipinnis</i>	Chile, Punta de Choros and surroundings	Tattoo skin disease		This paper
<i>Pseudorca crassidens</i>	Uruguay, Laguna Garzon	Fractures, hyperostosis, ankylosing spondylitis and osteomyelitis		This paper
<i>Pseudorca crassidens</i>	Ecuador, Santa Elena Peninsula	Whitish skin lesions		Félix and Haase (personal observations); this paper

continued

continued

SPECIES	COUNTRY, AREA	DISEASE, PATHOANATOMICAL DIAGNOSIS OR SYMPTOMATOLOGY	SUSPECTED RELATED ENVIRONMENTAL FACTORS	SOURCE
<i>Sotalia guianensis</i>	Brazil, Rio de Janeiro	Human-inflicted skin and skull traumas	Fishery interactions	Ramos <i>et al.</i> (2001)
<i>Sotalia guianensis</i>	Brazil, Rio de Janeiro	Vertebral destructive lesions, possibly due to tuberculosis		Siciliano <i>et al.</i> (2005) ²⁵
<i>Sotalia guianensis</i>	Brazil, Rio de Janeiro	Miscellaneous lesions, traumas and malformations of the skeleton		Fragoso (2001); Mendonça de Souza <i>et al.</i> (2006) ²¹ ; Laeta <i>et al.</i> (2006) ²⁰ ; this paper
<i>Sotalia guianensis</i>	Brazil, Rio de Janeiro	Dental and periodontal diseases		Fragoso (2001); this paper
<i>Sotalia guianensis</i>	Brazil, Sepetiba Bay	Whitish velvety skin lesions		Flach (2006) ¹⁹ ; this paper
<i>Sotalia guianensis</i>	Brazil, Sepetiba Bay	Scars and skin lesions	Fishery interactions	Flach (2006) ¹⁹ ; this paper
<i>Sotalia guianensis</i>	Brazil, Sepetiba Bay	Body injuries	Fishery interactions	Flach (2006) ¹⁹ ; this paper
<i>Sotalia guianensis</i>	Brazil, Sepetiba Bay	Body deformation and emaciation		Flach (2006) ¹⁹
<i>Sotalia guianensis</i>	Brazil, Sepetiba Bay	Tattoo skin disease (poxvirus)		This paper
<i>Sotalia guianensis</i>	Brazil, Baía Norte, Santa Catarina	Scars and skin lesions	Fishery interactions	P. Flores (unpublished data)
<i>Sotalia guianensis</i>	Venezuela, Zulia	Dental and periodontal diseases		This paper
<i>Sotalia guianensis</i>	Venezuela, Falcon and Zulia	Skull lesions and traumas	Fishery interactions	This paper
<i>Stenella coeruleoalba</i>	Ecuador, central coast	Periodontal disease		F. Félix (personal observations); this paper
<i>Stenella frontalis</i>	Venezuela, Aragua	Beak deformation		This paper
<i>Stenella frontalis</i>	Venezuela, Aragua	Extensive skin lesion on left flipper		This paper
<i>Stenella frontalis</i>	Venezuela, Aragua	Amputation of dorsal fin	Fishery interactions	This paper
<i>Tursiops truncatus (inshore)</i>	Brazil, Laguna, Santa Catarina	Lobomycosis-like disease	Biological and chemical pollution	Simões-Lopes <i>et al.</i> (1993)
<i>Tursiops truncatus (inshore)</i>	Brazil, Baía Norte, Santa Catarina	Lobomycosis-like disease	Biological and chemical pollution	Flores <i>et al.</i> (2005); this paper
<i>Tursiops truncatus (inshore)</i>	Brazil, Tramandat Estuary, Rio Grande do Sul	Lobomycosis	Biological and chemical pollution	This paper
<i>Tursiops truncatus (inshore)</i>	Brazil, Mampituba Estuary, Rio Grande do Sul	Lobomycosis-like disease	Biological and chemical pollution	Moreira and Moreno (2004) ²⁴ ; this paper
<i>Tursiops truncatus (inshore)</i>	Chile, Choros Island	Tattoo skin disease		This paper
<i>Tursiops truncatus (inshore)</i>	Chile, Palena	Vesicular cutaneous lesions	Aquaculture	Viddi <i>et al.</i> (2005) ²² ; this paper
<i>Tursiops truncatus (inshore)</i>	Colombia, Bahía Málaga	Lobomycosis-like disease	Biological and chemical pollution	This paper

continued

continued

SPECIES	COUNTRY, AREA	DISEASE, PATHOANATOMICAL DIAGNOSIS OR SYMPTOMATOLOGY	SUSPECTED RELATED ENVIRONMENTAL FACTORS	SOURCE
<i>Tursiops truncatus</i> (inshore)	Ecuador, Gulf of Guayaquil	Lobomycosis-like disease	Pollution, aquaculture	This paper
<i>Tursiops truncatus</i> (inshore)	Ecuador, Gulf of Guayaquil	Skin discolouration	Aquaculture	F. Félix (personal observations)
<i>Tursiops truncatus</i> (inshore)	Peru, central coast	Tattoo skin disease (poxvirus)		Van Bresse and Van Waerebeek (1996); Van Bresse <i>et al.</i> (2006a); this paper
<i>Tursiops truncatus</i> (inshore)	Peru, central coast	<i>Brucella</i> spp. infection		Van Bresse <i>et al.</i> (2001a)
<i>Tursiops truncatus</i> (inshore)	Peru, central and southern coast	Skull lesions, fractures and malformations	Fishery interactions (for some cases)	Montes (2003); Montes <i>et al.</i> (2004); this paper
<i>Tursiops truncatus</i> (inshore)	Peru, central and southern coast	Dental and periodontal diseases		Montes (2003); Montes <i>et al.</i> (2004); this paper
<i>Tursiops truncatus</i> (inshore)	Peru, entire coast	Hyperostosis and ankylosing spondylitis (skull and vertebrae)		Montes <i>et al.</i> (2004); this paper
<i>Tursiops truncatus</i> (inshore)	Peru, central coast	Lesions of the head, trunk and appendages	Fishery interactions	This paper
<i>Tursiops truncatus</i> (inshore)	Peru, Paracas	Whitish velvety skin lesions	Fish processing plants	J.C. Reyes and M. Echeagaray (personal observations); this paper
<i>Tursiops truncatus</i> (inshore)	Peru, Callao	Lobomycosis-like disease	Biological and chemical pollution	This paper
<i>Tursiops truncatus</i> (offshore)	Peru, central coast	Tattoo skin disease- poxvirus infection		Van Bresse and Van Waerebeek (1996); Van Bresse <i>et al.</i> (2006a)
<i>Tursiops truncatus</i> (offshore)	Peru, central coast	Genital papillomas		Van Bresse <i>et al.</i> (1996)
<i>Tursiops truncatus</i> (offshore)	Peru, central coast	Ovarian cysts		Van Bresse <i>et al.</i> (in prep.)
<i>Tursiops truncatus</i> (offshore)	Peru, central coast	Cetacean morbillivirus infection		Van Bresse <i>et al.</i> , 1998
<i>Tursiops truncatus</i> (offshore)	Peru, central coast	<i>Brucella</i> spp. infection		Van Bresse <i>et al.</i> (2001a)
<i>Tursiops truncatus</i> (offshore)	Peru, central and southern coast	Skull lesions, traumas and fractures		This paper
<i>Tursiops truncatus</i> (offshore)	Peru, central and southern coast	Dental and periodontal diseases		Montes <i>et al.</i> (2004); this paper
<i>Tursiops truncatus</i> (offshore)	Peru, central coast	Hyperostosis and ankylosing spondylitis (skull and vertebrae)		Montes <i>et al.</i> (2004); this paper
<i>Tursiops truncatus</i> (offshore)	Peru, central coast	Lesions of the head, trunk and appendages	Fishery interactions	This paper
<i>Tursiops truncatus</i> (offshore)	Peru, central coast	Skin discolouration		Van Bresse <i>et al.</i> (in prep.)
<i>Tursiops truncatus</i> (unknown stock)	Argentina, Patagonia	Uterine adenocarcinoma		Sanchez <i>et al.</i> (2002)

continued

conclusion

SPECIES	COUNTRY, AREA	DISEASE, PATHOANATOMICAL DIAGNOSIS OR SYMPTOMATOLOGY	SUSPECTED RELATED ENVIRONMENTAL FACTORS	SOURCE
<i>Tursiops truncatus</i> (unknown stock)	Argentina, Patagonia	Tattoo-like skin lesions		Sanchez <i>et al.</i> (2002)
<i>Tursiops truncatus</i> (unknown stock)	Brazil, Florianopolis	Lobomycosis-like disease		Flores <i>et al.</i> (2005) ¹⁸ ; this paper
<i>Tursiops truncatus</i> (unknown stock)	Brazil, Rio de Janeiro	Lesions of scapula		Siciliano <i>et al.</i> (2005) ²⁵
<i>Tursiops truncatus</i> (unknown stock)	Ecuador, Guayas	Ankylosing spondylitis (vertebrae)		M.P. Amador and W.E. Aguirre, (unpublished data); this paper
<i>Tursiops truncatus</i> (unknown stock)	Peru, central coast	Genital papillomas- papillomavirus infection		Van Bresse <i>et al.</i> (1996)
<i>Ziphius cavirostris</i>	Uruguay, Laguna Garzon	Multiple fractures of skeleton	Possible boat collision	E. Castiñeira and R. Möller (unpublished data); this paper

Besides their potential to kill outright, many types of fisheries may also provoke serious injuries and stress as well as influence the outcome of host-parasite interactions in the animals that survive an encounter (Van Bresse *et al.*, 1994; 1999; 2006b; Clark *et al.*, 2006). Polychlorinated biphenyls (PCBs) and related compounds might contribute to the severity of viral epizootics through toxicity at the level of the immune system (Aguilar and Borrell, 1994; Ross, 2002).

While a considerable number of pathology case studies have been implemented in South America, mainly over the past 15 years, no comprehensive overview of progress has so far been undertaken. In an effort to improve our understanding of pathological agents and processes that may co-determine modal health and potentially influence net recruitment and, indirectly, population size, we analysed data for 12 species of small cetaceans from the waters of eight SA countries and placed them in an epizootiological context. We further attempted to evaluate whether, and to what extent, human activities might contribute to traumata and malformations or facilitate the spread of certain infectious diseases.

MATERIAL AND METHODS

Study areas and species

In the period 1984-2007 the authors studied gross pathological evidence in about 7635 free-ranging, by-caught, and some stranded small cetaceans belonging to 12 species from the waters of Colombia, Ecuador, Peru, Chile, Argentina, Uruguay, Brazil and Venezuela (Table 2). Voucher data include images, field notes, museum specimens (skeletons) and others. Conditions of individuals studied ranged from 1 to 5 (alive to mummified or skeletal remains; Geraci and Lounsbury, 1993) but most were alive or freshly dead. A database including 55 parameters for each specimen presenting lesion(s) was compiled. The presence of suspected anthropogenic factors (fisheries, vessel collisions, fish farms, sewage and other pollution or any other type of coastal habitat encroachment) within, or in the vicinity of, each studied population's habitat was noted. Some subsets of data were previously presented at conferences (Bolaños-Jiménez and Bermúdez, 1996²³; Moreira and Moreno, 2004²⁴; Flores *et al.*, 2005¹⁸; Siciliano *et al.*, 2005²⁵; Viddi *et al.*, 2005²²; Flach, 2006¹⁹; Laeta *et al.*, 2006²⁰; Mendonça de Souza *et al.*, 2006²¹), used in Master's theses (Fragoso, 2001; Montes-Iturrizaga, 2003) or published (Ramos *et al.*, 2001; Montes *et al.*, 2004; Van Bresse *et al.*, 2006b).

²³ Bolaños-Jimenez, J. and Bermudez, V. (1996) *Un caso de malformaciones óseas en delfín estuarino (Sotalia fluviatilis) en el Estado Zulia*. Page 101 in Libro Memorias, III Congreso de Ciencias Veterinarias "Eduardo Mendoza Goiticoa", 29 September- 4 October 1996, Maracay, AR, Venezuela.

²⁴ Moreira, M.B and Moreno, I.B. (2004) *Patologia epitelial em Tursiops truncatus no Rio Mampituba, sul do Brasil*. Page 92. in Abstracts, XI Reunión de Especialistas em Mamíferos Acuáticos del América Del Sur, 12-17 September, 2004, Quito, Ecuador.

²⁵ Siciliano, S., Hassel, L.B., Alves, V.C., Dittmar, K. and Mendonça de Souza, S.M.F. (2005) *Pathological findings in the skeletons of small cetaceans from Rio de Janeiro, Brazil*. Page 51 in: Abstracts, 1st Paleopathology Association Meeting in South America, 25-29 July 2005, Escola Nacional de Saúde Pública/FIOCRUZ, Rio de Janeiro, RJ, Brazil.

Table 2. Composition of subsamples of small cetaceans examined in this study, including sampling areas, sampling periods and the prevalence of diseases, malformations and traumas.

SPECIES	HABITAT	SAMPLING AREA	SAMPLING PERIOD	SPECIMENS	TOTAL N EXAMINED	N OBSERVED ALIVE OR FRESHLY DEAD	N OBSERVED SKELETAL MATERIAL	TOTAL N WITH LESIONS	DISEASES, TRAUMATA, LESIONS AND MALFORMATIONS AFFECTING:		
									BONES	SKIN	OTHER
<i>Cephalorhynchus commersonii</i>	Neritic	Puerto Deseado, AR	2001-2007	Free-ranging	unknown	3	0	3	0	3	0
<i>Cephalorhynchus eutropia</i>	Inshore/estuarine	N. Patagonia, CL	2003-2004	Free-ranging	13	13	0	4	0	4	0
<i>Delphinus capensis</i>	Offshore/neritic	Entire coastline, PE	1985-2000	By-caught	930	859	103 skulls & calvariae	120	38	98	11
<i>Delphinus delphis</i>	Unknown	N Gulf of Guayaquil and central coast, EC	1992 & 1998	Stranded	28	27	1 skeleton	2	1	1	0
<i>Lagenorhynchus australis</i>	Inshore/estuarine	N Patagonia, CL	2003-2004	Free-ranging	45	45	0	1	0	1	0
<i>Lagenorhynchus obscurus</i>	Offshore/neritic	Entire coastline, PE	1984-2001	By-caught and stranded	4281	4251	46 skulls & calvariae	172	13	143	18
<i>Phocoena spinipinnis</i>	Inshore/neritic	Entire coastline, PE	1985-1999	By-caught	902	872	37 skulls & calvariae	97	3	87	17
<i>Pseudorca crassidens</i>	Inshore/neritic	Punta de Choros and surroundings, CL	1998-2002	By-caught	3	3	0	3	0	3	0
<i>Pseudorca crassidens</i>	Offshore/pelagic	Laguna Garzon, UY	1998-2000	Stranded	1	0	1	1	1	0	0
<i>Pseudorca crassidens</i>	Offshore/pelagic	Santa Elena, EC	1992	Stranded	28	28	0	1	0	1	0
<i>Sotalia guianensis</i>	Inshore/estuarine	Estados Zulia and Falcón, VE	1992-2003	By-caught and stranded	46	0	46 skulls	7	7	0	0
<i>Sotalia guianensis</i>	Inshore/estuarine	N Rio de Janeiro, BR	1987-1998	By-caught and stranded	53	0	53 whole skeletons	34	34	0	0
<i>Sotalia guianensis</i>	Inshore/estuarine	N Rio de Janeiro, BR	2001-2006	By-caught and stranded	31	0	31 axial skeletons	15	15	0	0
<i>Sotalia guianensis</i>	Inshore/estuarine	Sepetiba Bay, BR	2005-2007	Free-ranging	168	168	0	42	0	30	13
<i>Stenella frontalis</i>	Inshore/neritic	Aragua, VE	1996-2000 & 2005	Free-ranging	100-400	100-400	0	3	0	1	2
<i>Tursiops truncatus</i>	Inshore/neritic	Bahía Málaga and surroundings, CO	2005-2006	Free-ranging	37	37	0	2	0	2	0
<i>Tursiops truncatus</i>	Inshore/estuarine	Gulf of Guayaquil, EC	1990-1991	Free-ranging	441	441	0	8	0	8	0
<i>Tursiops truncatus</i>	Inshore/neritic	Central coast, PE	2006	Free-ranging	unknown	1	0	1	0	1	0
<i>Tursiops truncatus</i>	Inshore/neritic	Entire coastline, PE	1984-2000	By-caught and stranded	37	19	26 skulls & calvariae	14	10	1	3

continued

continued

SPECIES	HABITAT	SAMPLING AREA	SAMPLING PERIOD	SPECIMENS	TOTAL N EXAMINED	N OBSERVED ALIVE OR FRESHLY DEAD	N OBSERVED SKELETAL MATERIAL	TOTAL N WITH LESIONS	DISEASES, TRAUMATA, LESIONS AND MALFORMATIONS AFFECTING:		
									BONES	SKIN	OTHER
<i>Tursiops truncatus</i>	Inshore/neritic	Paracas Bay, PE	1997 & 2004-2006	Free-ranging	70	70	0	8	0	6	3
<i>Tursiops truncatus</i>	Inshore/neritic	Choros Island, CL	1998	Free-ranging	1	1	0	1	0	1	0
<i>Tursiops truncatus</i>	Inshore/neritic	N Patagonia, CL	2003-2004	Free-ranging	2	2	0	1	0	1	0
<i>Tursiops truncatus</i>	Inshore/neritic	Santa Catarina, BR	1993-2004	Free-ranging dolphins	39	39	0	2	0	2	0
<i>Tursiops truncatus</i>	Inshore/estuarine	Tramandaí Estuary, Rio Grande do Sul, BR	1991-2007	Free-ranging dolphins	10	10	0	2	0	2	0
<i>Tursiops truncatus</i>	Inshore/estuarine	Mampituba Estuary, Rio Grande do Sul, BR	2003-2004	Free-ranging dolphins	unknown	3	0	1	0	1	0
<i>Tursiops truncatus</i>	Offshore/pelagic	Entire coastline, PE	1984-2000	By-caught and stranded	85	68	42 skulls & calvariae	40	29	12	10
<i>Tursiops truncatus</i>	Offshore & inshore	N Rio de Janeiro, BR	2001-2007	By-caught and stranded	9	1	8 skeletons	5	5	1	0
<i>Tursiops truncatus</i>	Unknown	N Gulf of Guayaquil, EC	1999	Bone remains	4	0	4 axial skeletons	1	1	0	0
<i>Ziphius cavirostris</i>	Offshore/pelagic	Laguna Garzon, UY	1998-2000	Stranded	1	0	1	1	1	0	0

Country names (sampling area) according to ISO abbreviations.

Skeletal material

The skulls and skeletons of 399 dolphins and porpoises from Ecuador, Peru, Uruguay, Brazil and Venezuela (Table 2) were examined for the presence of osteopathology and abnormalities. Particular attention was paid to Crassicaudiasis, apparently irreversible, basket-like cranial lesions caused by *Crassicauda* spp. nematodes because of high potential for pathogenicity and mortality (e.g. Perrin and Powers, 1980; Raga *et al.*, 1982; Dailey, 1985). Skeletal material is deposited at cetacean reference collections including the Museo de Delfines (Pucusana, Peru), Áreas Costeras y Recursos Marinos (ACOREMA, Pisco, Peru), Grupo de Estudos de Mamíferos Marinhos da Região dos Lagos (GEMM-Lagos, Brazil), Universidade Estadual do Norte Fluminense-LCA (Brazil), Museu de Zoologia da Universidade de São Paulo (Brazil), Museo de Ballenas (FEMM, Ecuador), Museo de la Estación Biológica Rancho Grande (EBRG, Ministerio del Ambiente – MINAMB, Venezuela) and Exhibición Museo del Mar (Maldonado, Uruguay).

Individuals were considered cranially mature when presenting advanced fusion in the frontal-supraoccipital or premaxillary-maxillary sutures or, if these were damaged, in at least two of five other indicative cranial sutures (Van Waerebeek, 1992; 1993).

Recently dead specimens

Carcases of 6128 small cetaceans from Ecuador, Peru, Chile and Brazil were examined, predominantly under field conditions (e.g. fish markets and beaches), for macroscopical lesions, malformations and cutaneous diseases. Observations were opportunistic in Peru until 1990. Dedicated research in 1993-95 allowed practically unbiased prevalence rates to be estimated for by-caught dusky dolphins (*Lagenorhynchus obscurus*), offshore and inshore common bottlenose dolphins (*Tursiops truncatus*), long-beaked common dolphins (*Delphinus capensis*) and Burmeister's porpoises (*Phocoena spinipinnis*). Sexual maturity was determined, in females, from the presence of at least one corpus luteum or corpus albicans in one of the ovaries, or evidence of lactation or pregnancy (visible foetus); in males, if seminal fluid was detected macroscopically in at least one freshly cut epididymis. When sexual maturity status could not be determined directly, it was inferred based on an approximation for the mean standard body length (SL) at sexual maturation for these populations (Van

Waerebeek *et al.*, 1990; Van Waerebeek, 1992; Reyes and Van Waerebeek, 1995; Van Bresseem *et al.*, 2006b).

Free-ranging dolphins

The prevalence of evident dermatologic disease, gross body deformations and traumata, including extensive scarring or mutilation, was studied in a minimum of 1196 free-ranging dolphins (Table 2) from images taken during photo-identification surveys from small boats or from shore (Félix, 1997; Bolaños-Jiménez *et al.*, 1998; 2007; Sanino and Yáñez, 2001; Reyes *et al.*, 2002²⁶; Ott, 2004; Flores *et al.*, 2005¹⁸; Viddi *et al.*, 2005²²; Flach, 2006¹⁹; Flores and Fontoura, 2006). Dolphins were individually identified from natural marks (Würsig and Jefferson, 1990). The maturity class (calf, juvenile, adult) of *T. truncatus* from Colombia's Bahía Málaga (and surroundings), Chile, the Gulf of Guayaquil (Ecuador) and southern Brazil, of Chilean dolphins (*Cephalorhynchus eutropia*) and Guiana dolphins (*Sotalia guianensis*) from Sepetiba Bay, Brazil, was estimated from relative body size and behavioural clues (Wells *et al.*, 1980; Shane, 1990) or from the period of residence. Maturity of Atlantic spotted dolphins (*Stenella frontalis*) from Venezuelan waters was estimated from the degree of body spotting (Herzing, 1997). Dedicated surveys to assess the presence of skin conditions and traumata were conducted in *C. eutropia*, Peale's dolphin (*Lagenorhynchus australis*) and *T. truncatus* from Chile as well as in *S. guianensis* from Sepetiba Bay (Viddi *et al.*, 2005²²; Flach, 2006¹⁹). Populations of inshore *T. truncatus* from Paracas (Peru), the Gulf of Guayaquil (Ecuador), and Rio Grande do Sul and Santa Catarina (Brazil) have been the objects of long-term field research (Oliveira *et al.*, 1996²⁷; Félix, 1997; Reyes *et al.*, 2002²⁶; Flores *et al.*, 2005¹⁸; Flores and Fontoura, 2006). In these cases, prevalence of diseases and traumata could be estimated with precision.

Sexual and ontogenetic variation

With sample sizes permitting, we examined whether disease prevalence varied with sex and sexual or cranial maturity as a proxy for age. Prevalence refers to the amount of lesions and disease in samples and subsamples at the time of examination, without distinction between old and new cases (Thrusfield, 1986). Significance of differences in prevalence (≤ 0.05) was verified with chi-square contingency tests or one-tailed Fisher's exact tests (Swinscow, 1981).

²⁶ Reyes, J.C., Echegaray, M. and De Paz, N. (2002) *Distribución, comportamiento y conservación de cetáceos en el área Pisco Paracas*. Pages 136-144 in Mendo, J. and Wolff, M. (Eds). *Memorias I Jornada Científica Reserva Nacional de Paracas*. Universidad Nacional Agraria, Lima, Peru.

²⁷ Oliveira, L.R., Ott, P.H., Borges-Martins, M. and Danilewicz, D. (1996) *Fotoidentificação da população de botos (Tursiops truncatus) do estuário do Rio Tramandaí, RS, Brasil*. p.250 in XXI Congresso Brasileiro de Zoologia, 1996, Porto Alegre, Brasil.

Results

Cutaneous diseases, wounds, scars and traumata were observed in large numbers of small cetaceans from Colombia, Ecuador, Peru, Chile, Argentina, Brazil and Venezuela (Table 2). For instance, all populations and ecotypes of *T. truncatus* from South America exhibited skin diseases. Due to the very large amount of data we have limited this preliminary analysis to diseases that are likely of highest concern in relation to environmental factors and anthropogenic effects.

Cutaneous diseases

➤Tattoo skin disease

Tattoo skin disease (TSD) is characterized by very typical, irregular, grey, black or yellowish, stippled lesions that may occur on any part of the body but show a preferential corporal distribution depending on the species (Van Bresseem and Van Waerebeek, 1996). The prevalence of tattoo positive dolphins and porpoises from the SE Pacific and SW Atlantic is presented in Table 3. TSD is highly prevalent and likely endemic in Peruvian small cetaceans and, at least in delphinids, affects predominantly juveniles. The earliest confirmed case in Peru is a *D. capensis* landed in January 1986 (Van Bresseem *et al.*, 2006b). The apparent low prevalence in inshore *T. truncatus* from the Bay of Paracas (Peru) is likely related to the fact that photo-identification images permitted only dorsal parts of the body to be examined and that tattoos may be difficult to spot on the dark grey skin. The disease is also present in the short-beaked common dolphin (*Delphinus delphis*) from Ecuador, *P. spinipinnis* and *T. truncatus* from Punta de Choros and surroundings (Chile) and, possibly, in the Commerson's dolphin (*Cephalorhynchus commersonii*) from Argentine Patagonia. In inshore *C. eutropia* from southern Chile and *S. guianensis* from Sepetiba Bay (23°S, 44°W), southern Rio de Janeiro state (Brazil), tattoos were observed only in adults (Figure 1a,b). However, 167 of the 168 *S. guianensis* photo-identified during this study were adults. Both active tattoos (dark gray or black stippled lesions, Figure 1b) and tattoo remains (light gray marks, Figure 1c) were seen in the Sepetiba dolphins. TSD was not detected in 91 *S. guianensis* accidentally caught off northern Rio de Janeiro (RJ) in 1988-2004 (Van Bresseem *et al.*, 2003a; Di Benedetto, pers. obs.) but may represent a threat for this population through contacts with dolphins from southern RJ.

➤Rounded cutaneous lesions

Large rounded lesions with an orange or dark outline and a light inner colour were seen in a *C. commersonii* from Argentine Patagonia in 2001 and a *C. eutropia* calf from southern Chile in 2003 (Figures 2a,b). Their irregular rounded shape evoked superinfected tattoo lesions seen, for instance, in a *T. truncatus* calf from the

Sado Estuary, Portugal (Van Bresseem *et al.*, 2003b) but their aetiology is unknown. The lesions were extensive in both dolphins and the calf apparently died six weeks after the lesions were first noted. A similar but much smaller orange, rounded skin mark was seen in another *C. commersonii* from Puerto Deseado, Argentina while at least six dark orange skin marks with an irregular outline were detected in a *S. guianensis* from Sepetiba Bay. In these two cases the lesions also showed the irregular, rounded shape characteristic for tattoo-like lesions. Diatoms have been found in orange skin marks on harbour porpoises (*Phocoena phocoena*) from Washington state, northeastern Pacific (Norman *et al.*, 2004) and could have superinfected existing lesions in SA small cetaceans.

➤Whitish velvety lesions

Whitish lesions with a velvety appearance and often associated with unrelated wounds, scars and tooth rakes were observed on the beak, back, dorsal fin and flukes of inshore *T. truncatus* from the Bay of Paracas, *S. guianensis* from Sepetiba Bay and a false killer whale (*Pseudorca crassidens*) stranded in Santa Elena, Ecuador (Table 3; Figures 3a,b,c,d). In two photo-identified common bottlenose dolphins in the Bay of Paracas in 2004-2005, dorsal fin skin lesions ulcerated, exposing the underlying connective tissues, and subsequently cicatrised over a period of 2-6 months (Figures 3c,d).

➤Lobomycosis-like disease (LLD)

Whitish to slightly pink, verrucous lesions, often in pronounced relief, that may ulcerate and evoke lobomycosis (Migaki *et al.*, 1971) were observed in free-ranging inshore *T. truncatus* from Colombia, Ecuador, Peru and Brazil (Table 3; Figures 4a,b,c,d). The lesions were either disseminated or localized and affected the beak, dorsal fin, dorsum, flanks, belly, tailstock and flukes. In Bahía Málaga and surroundings, Colombia, LLD was first observed in two adults from a group of six in August 2005. Two dolphins with LLD, possibly the same as those seen in 2005, were sighted in February 2006 among a group of seven. In addition, single dolphins with LLD were repeatedly photographed in the period February-October 2006 among groups of 4 to 37 individuals (Figure 4d). Two mature dolphins from Tramandaí estuary, southern Brazil, known since 1991, developed LLD over several years. The lesions were observed on the dorsal fin of the first one in May 1999. The dolphin was last sighted and photographed in August 2003 (Hoffmann, 2004), and probably died since. The second dolphin (GEMARS 1259), a male, was first seen with LLD on the rostrum in December 2002. It died in November 2005 with widespread lesions (Figure 4b). Histological examination confirmed the visual diagnostic of lobomycosis (GEMARS, unpublished data). In the estuary of Mampituba river, southern Brazil, about 80 km north of Tramandaí, another *T. truncatus* was first noticed with LLD on the flanks in September 2003.

Table 3. Prevalence of skin diseases in odontocetes from South America.

COUNTRY & SPECIES	HABITAT	REGION	SAMPLING PERIOD	SPECIMENS	TATTOOS		SKIN DISEASES		LOBOMYCOSIS-LIKE	
					N	Prev	N	Prev	N	Prev
Colombia										
<i>Tursiops truncatus</i>	Inshore/neritic	Bahía Málaga and surroundings	2005-2006	Free-ranging	ne	ne	ne	ne	37 ^a	5.4%
Ecuador										
<i>Delphinus delphis</i>	Offshore/pelagic	Central coast	1992	By-caught	11	9.1%	ne	ne	ne	ne
<i>Pseudorca crassidens</i>	Offshore/pelagic	Santa Elena Peninsula	1992	Free-ranging	ne	ne	28	3.6%	ne	ne
<i>Tursiops truncatus</i>	Inshore/estuarine	Gulf of Guayaquil	1990-1991	Free-ranging	ne	ne	ne	ne	441	1.6%
Peru										
<i>Delphinus capensis</i>	Offshore/neritic	Central coast	1993-1994	By-caught	54	61.1%	54	0%	54	0%
<i>Lagenorhynchus obscurus</i>	Offshore/neritic	Central coast	1993-1994	By-caught	196	34.7%	196	0%	196	0%
<i>Phocoena spinipinnis</i>	Inshore/neritic	Central coast	1993-1994	By-caught	77	62.3%	77	0%	77	0%
<i>Tursiops truncatus</i>	Inshore/neritic	Southern coast	2004-2006	Free-ranging	70	1.4%	70	7.1%	70	0%
<i>Tursiops truncatus</i>	Offshore/pelagic	Central coast	1993-1994	By-caught	12	41.6%	12	0%	12	0%
Chile										
<i>Cephalorhynchus eutropia</i>	Inshore/neritic	Northern Patagonia	2003	Free-ranging	13	7.7-15.4%	13	0%	13	0%
Brazil										
<i>Sotalia guianensis</i>	Inshore/estuarine	Sepetiba Bay	2005-2007	Free-ranging	168	4.1-5.9% ^b	168	2.4%	168	0%
<i>Tursiops truncatus</i>	Inshore/neritic	Santa Catarina (Baía Norte)	1993-2004	Free-ranging	ne	ne	ne	ne	39	5.1%
<i>Tursiops truncatus</i>	Inshore/estuarine	Tramandaí Estuary	1991-2007	Free-ranging	ne	ne	ne	ne	10	20%
<i>Tursiops truncatus</i>	Inshore/estuarine	Mampituba Estuary	2003-2004	Free-ranging	ne	ne	ne	ne	3	33%

N = total number of specimens examined, Prev = prevalence, ne = not examined. ^athe total number of dolphins of this community is estimated at 60; ^b7 dolphins showed active lesions, 3 others displayed tattoo remains.




Figure 1a. Tattoo lesions in an adult *Cephalorhynchus eutropia* (CEU-012) from southern Chile.



Figure 1b. Tattoo lesions and emaciation in an adult *Sotalia guianensis* (SEP-007) from Sepetiba Bay (Brazil).



Figure 1c. Tattoo remains on the dorsal fin and back of a *Sotalia guianensis* (SEP-021) from Sepetiba Bay (Brazil).



Figure 2a. Large, rounded lesions in a calf *Cephalorhynchus eutropia* (CEU-37) from northern Patagonia (Chile).



Figure 2b. Large rounded lesions in a *Cephalorhynchus commersonii* (CCO-SN) from Patagonia (Argentina).



Figure 3a. Whitish, velvety lesions associated with a deep wound in an adult *Sotalia guianensis* (SEP-033) from Sepetiba Bay (Brazil).



Figure 3b. Whitish, velvety lesions associated with scars in an inshore *Tursiops truncatus* (PBD-060) from Paracas Bay (Peru).



Figure 3c. Ulcerated whitish lesions on the dorsal fin of an inshore *Tursiops truncatus* (PBD-015) from Paracas Bay (Peru) on 10 November 2004.



Figure 3d. Healed lesions on the dorsal fin of an inshore *Tursiops truncatus* (PBD-015) from Paracas Bay (Peru) on 18 January 2005.




Figure 4a. Lobomycosis-like disease in an adult, inshore *Tursiops truncatus* (TPBN-03) from Baia Norte, Santa Catarina (Brazil).



Figure 4b. Lobomycosis in an adult male, inshore *Tursiops truncatus* (GEMARS-1259) from the Tramandaí Estuary (Brazil).

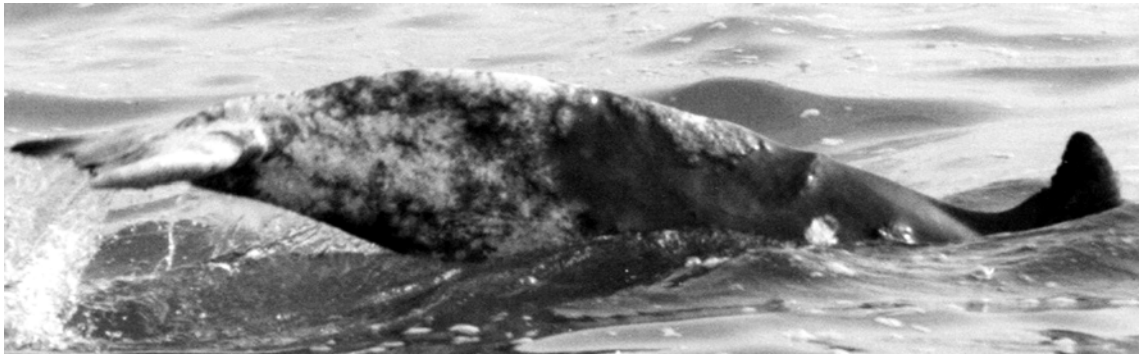


Figure 4c. Lobomycosis-like disease in estuarine *Tursiops truncatus* (FEMM-22, -148, -149, -160, -282, -318 and-319) from the Gulf of Guayaquil (Ecuador).



Figure 4d. Lobomycosis-like disease in an inshore *Tursiops truncatus* FYUB-BM-0206G1-1 from Bahía Málaga and surroundings (Colombia).

It presented widespread lesions on the dorsum in March 2004 (Moreira and Moreno, 2004²⁴). Further north two *T. truncatus* from Baía Norte also had LLD. In one of them the disease lasted at least 20 months (Flores *et al.*, 2005¹⁸). One *T. truncatus* sighted off Callao, Peru's main port, in December 2006 showed extensive lobomycosis-like lesions and ulceration of the dorsal fin. Importantly, despite observations at hundreds of both captured and free-ranging individuals by CEPEC and ACOREMA scientists along the entire Peruvian coast (Reyes *et al.*, 2002²⁶; unpublished data), this condition was never seen in the period 1984-2005. Hence, LLD is considered an emerging disease in Peru.

➤ Vesicular lesions

Vesicles were noticed in an adult female *T. truncatus* (Figure 5) from Palena, Chile in December 2003. Several ulcerated lesions were observed on the flanks of a *T. truncatus* stranded in RJ in March 2007. Ulcerative dermatitis caused by *Aeromonas hydrophila* was described in *T. truncatus* (Cusick and Bullock, 1973). A calicivirus (cetacean calicivirus 1) caused ulcerative vesicular lesions in two captive Atlantic *T. truncatus* (Smith *et al.*, 1983).

Miscellaneous traumata

Wounds and extensive traumata affected the head, trunk and appendages of different species and populations (Tables 4 and 5). A large percentage of the cutaneous wounds, cuts, large or deep scars and other traumata observed in all populations studied was likely related to net entanglements and to a lesser extent to boat collisions (Tables 4 and 5). In 17 cases involving *T. truncatus* (both ecotypes, Peru), *P. spinipinnis* (Peru), *S. guianensis* (Brazil) and *Stenella frontalis* (Venezuela) the dorsal fin, flippers and flukes were severely injured resulting in partial or complete amputations and

deformations (Figure 6a; Table 5). Interactions with fisheries are thought to have caused these injuries in at least 70.5% of the affected animals. In addition, remains of nylon gillnets were seen in five *S. guianensis* from Sepetiba Bay (Figure 6b) and two from northern RJ (Fragoso, 2001; Ramos *et al.*, 2001; Table 5). In a number of species, incisive wounds and scars possibly inflicted by propellers are currently under study, in an effort to identify confirmed cases (see Van Waerebeek *et al.*, 2007, this volume). A healing, large shark bite was observed in at least one free-ranging *S. guianensis* from Sepetiba Bay (Figure 6c).

Lesions of the skeleton

Lesions of the skeleton were classified into four categories (Table 6). Prevalence of osteopathology ranged from a low 5.4% in Peruvian *P. spinipinnis* up to a high 69.1% in Peruvian offshore *T. truncatus*.

➤ Malformations

BRAZIL. Among 53 *S. guianensis* collected in 1987-1998 in northern RJ, congenital malformations were detected in 7.6% of the skulls and 9.4% of axial skeletons (Table 6). They affected the maxillaries, premaxillaries, mandibles, occipital, cervical and thoracic vertebrae, sternum and ribs. Three mature females showed multiple malformations of the whole skeleton. Malformations of the axial skeleton characterized by an incomplete closure of the vertebral arch of the seventh cervical vertebra and sometimes associated with the presence of cervical ribs, were observed in 48.4% of 31 *S. guianensis* gathered in the same region in 2001-2006 (Figure 7). Most (66.7%) affected specimens were immature. The spinal processes of some thoracic and caudal vertebrae were abnormally curved in an immature female inshore *T. truncatus* from northern RJ.



Figure 5. Vesicles on the skin of a female *Tursiops truncatus* (TTR-143) from southern Chile.

Table 4. Prevalence of externally visible traumata, cutaneous wounds^a, large or deep scars and abscesses in small cetaceans from South America, with an indication (%) of possible human-related origin.

COUNTRY & SPECIES	REGION	SAMPLING PERIOD	CUTANEOUS WOUNDS, SCARS AND ABSCESSES				TRAUMATA (EXTERNALLY VISIBLE)			
			N	NPOS	PREV	HR	N	NPOS	PREV	HR
Peru										
<i>Delphinus capensis</i>	Central coast	1990-1994	54	15	27.8%	80%	545	3	0.6%	100%
<i>Lagenorhynchus obscurus</i>	Central coast	1993-1994	240	13	5.4%	30.8%	240	4	1.7%	25%
<i>Phocoena spinipinnis</i>	Central coast	1991-1994	106	22	20.8%	45.5%	106	2	1.9%	50%
<i>Tursiops truncatus, inshore</i>	Central coast	1985-1989	16	0	0%	-	16	3	18.8%	66.7%
<i>Tursiops truncatus, inshore</i>	Paracas Bay	2004-2006	70	1	1.4%	0%	70	3	4.3%	66.7%
<i>Tursiops truncatus, offshore</i>	Central coast	1985-1990	52	2	3.8%	0%	52	4	7.7%	28.6%
<i>Tursiops truncatus, offshore</i>	Central coast	1993-1994	13	2	15.4%	50%	13	1	7.7%	100%
Chile										
<i>Lagenorhynchus australis</i>	Northern Patagonia	2003	45	1	2.2%	100%	-	45	0	0%
Brazil										
<i>Sotalia guianensis</i>	Sepetiba Bay	2005-2007	168	8	4.8%	87.5%	168	10	6%	80%
Venezuela										
<i>Stenella frontalis</i>	Central coast	2005	200	1	0.5%	indet	200	3	1.5%	100%
<i>Stenella frontalis</i>	Central coast	1996-2000	ne	ne	ne	ne	100-400	1	0.25-1%	indet

N = number of specimens examined, Npos= number of positive, prev = prevalence, HR = human related, ne = not examined, indet = indetermined; ^a = not including harpoon wounds that caused death.

PERU. Congenital malformations of the skull were observed in *L. obscurus*, *D. capensis* and inshore *T. truncatus* but not in *P. spinipinnis* and offshore *T. truncatus* (Table 6). Severe malformations involved the cranium of a *L. obscurus* (Figure 8) and a *D. capensis* (Van Bresse *et al.*, 2006b). In other dolphins lesions were benign (brachygnathia, prognathism, beak deviation) and likely did not interfere with feeding or other vital activities.

➤ Fractures and other traumata

BRAZIL. Among 53 *S. guianensis* from northern RJ collected in 1987-1998, the following percentages showed fractures affecting the ribs (20.8%), scapulae (1.9%) and vertebrae (22.6%) including cervical (9.5%), thoracic (3.8%), lumbar L6-L8 (15.1%) and caudal (5.7%) vertebrae. Among *S. guianensis* collected in the same region in 2001-2006, fractures of the hemi-arches of C7, T1 and T2 were observed in a mature specimen of unknown sex (3.2%).

Table 5. Traumata, large or deep scars and fractures possibly caused by interactions with fisheries and boats in small cetaceans from South American waters.

SPECIES & SPECIMENS	HABITAT	DATE (D/MO/YR)	LOCALITY	SEX	SL (CM)	MATURITY	LESIONS
<i>Delphinus capensis</i>							
AGG-405	Offshore/neritic	05/09/91	Central Peru	F	167.5	Imm	Nodule on tailstock: chronic fibrotic reaction due to infection or trauma
KVW-994	Offshore/neritic	13/12/86	Central Peru	M	229	Imm	Two holes with irregular edges in occipital bone close to left condyle
MFB-86	Offshore/neritic	26/3/93	Central Peru	M	200.7	Imm	Big scar on joint left flipper
MFB-189	Offshore/neritic	13/5/93	Central Peru	M	232	Mat	Scars on beak
MFB-218	Offshore/neritic	15/5/93	Central Peru	M	209	Imm	Scar on right mandibula below eye
MFB-219	Offshore/neritic	15/5/93	Central Peru	M	192	Imm	Scar on left side of head and on flipper
MFB-225	Offshore/neritic	27/5/93	Central Peru	F	>171	Imm	One scar on right side of melon (28x20mm)
MFB-228	Offshore/neritic	6/6/93	Central Peru	M	184.5	Imm	One scar (41x25mm) on right side of beak, below the eye
MFB-232	Offshore/neritic	6/6/93	Central Peru	M	188.5	Imm	One scar on right side of head (85x30mm).
MFB-258	Offshore/neritic	8/8/93	Central Peru	M	197.3	Imm	One scar on head
MFB-264	Offshore/neritic	8/8/93	Central Peru	M	197	Imm	One scar on right side of tail stock
MFB-281	Offshore/neritic	12/8/93	Central Peru	M	204	Imm	One scar on the joint of right flipper
MFB-297	Offshore/neritic	21/8/93	Central Peru	F	192	Imm	Large scar on tailstock
MFB-312	Offshore/neritic	27/10/93	Central Peru	M	200	Imm	One scar below right eye, another at the level of right flipper joint
RBC-21	Offshore/neritic	26/3/93	Northern Peru	M	234	Mat	Insertion of flipper broken
RBC-22	Offshore/neritic	26/3/93	Northern Peru	F	233	Mat	Insertion of flipper broken
<i>Lagenorhynchus australis</i>							
FV-45	Inshore/estuarine	26/1/03	Northern Patagonia, CL	Unk	Unk	Mat	Wounds on left flank, close to tailstock
<i>Lagenorhynchus obscurus</i>							
MFB-107	Offshore/neritic	30/3/93	Central Peru	M	192.8	Mat	Scar at the corners of beak
MFB-252	Offshore/neritic	16/7/93	Central Peru	M	137	Calf	Tip of dorsal fin deformed
MFB-403	Offshore/neritic	17/11/93	Central Peru	F	194	Mat	Scar on left flipper
MFB-463	Offshore/neritic	8/12/93	Central Peru	F	191.5	Mat	Scars on internal and external side of left flipper.
MFB-535	Offshore/neritic	5/6/94	Central Peru	M	116.5	Calf	Healing linear wounds on right flank, below and in front of dorsal fin
MFB-806	Offshore/neritic	2/6/94	Central Peru	Unk	Unk	Unk	Fractures and traumas of right maxillary, right pterygoid and left mandible caused by a bullet
<i>Phocoena spinipinnis</i>							
KOS-270	Inshore/neritic	4/12/93	Central Peru	F	155.5	Mat	Two scars on the mouth corner

continued

continued

SEP-33	Inshore/estuarine	1/7/05	Sepetiba Bay, BR	Unk	Unk	Mat	Deep healed wound on the anterior basis of dorsal fin
EBRG-21069	Inshore/estuarine	19/9/95	Estado Zulia, VE	Unk	Unk	unk	Cavity of about 110mm ² on the right mandible behind the most posterior teeth
EBRG-18554	Inshore/estuarine	12/91	Estado Falcon, VE	Unk	Unk	Imm	Peri-mortem trauma in the ascending process of left maxillary
EBRG-24121	Inshore/estuarine	9/11/02	Estado Zulia, VE	Unk	Unk	Imm	Peri-mortem trauma affecting the left premaxillary, maxillary, mandible and occipital
<i>Stenella frontalis</i>							
JBJSF-05-03	Inshore/neritic	15/9/05	Aragua, VE	Unk	Unk	Imm	Large wound on left flipper
JBJSF-05-04	Inshore/neritic	15/9/05	Aragua, VE	Unk	Unk	Imm	Partial amputation of dorsal fin and large scar on left side of the back
JBJSF-05-05	Inshore/neritic	15/9/05	Aragua, VE	Unk	Unk	Unk	Complete amputation of dorsal fin
<i>Tursiops truncatus</i>							
AJR-46	Inshore/neritic	29/3/86	Central Peru	M	277.5	Mat	Left flipper missing entirely: humerus had been severed earlier in life and healed
MWC-25	Inshore/neritic	14/12/87	Central Peru	Unk	Unk	Mat	Healed fracture of left mandible
KVW-542	Inshore/neritic	27/1/87	Central Peru	M	308	Mat	Healed fracture of left mandible
KVW-1061	Inshore/neritic	18/3/88	Central Peru	M	269.5	Imm	Tip of right flipper cut-off
PBD-29	Inshore/neritic	26/4/04	Paracas Bay, PE	Unk	Unk	Unk	Flukes partially amputated
PBD-007	Inshore/neritic	1997	Paracas Bay, PE	Unk	Unk	Unk	A deep cut on the anterior border of the dorsal fin, near its anterior insertion.
JCR-673	Offshore/pelagic	31/1/86	Central Peru	M	288	Mat	Distal end of left flipper missing
JCR-1649	Offshore/pelagic	26/5/90	Central Peru	M	297	Mat	Unhealed old fracture of left mandible and presence of a large hole
KVW-359	Offshore/pelagic	26/4/86	Central Peru	M	272	Imm	Tip of left flipper missing
KVW-1026	Offshore/pelagic	26/1/88	Central Peru	M	299	Mat	Healed fracture of left mandible
MFB-175	Offshore/pelagic	10/5/93	Central Peru	Unk	289	Mat	Healed fracture of right mandible
MFB-702	Offshore/pelagic	10/7/94	Central Peru	F	272	Mat	Scars all over body, right flipper partially amputated and healed
GEMM-81	Indeterminate	26/6/05	Rio de Janeiro, BR	M	290	Mat	Fracture of ribs and vertebrae
<i>Ziphius cavirostris</i>							
ECL-1	Offshore/pelagic	19/1/07	Laguna Garzon, UY	F	600	Mat	Fractures of the mandible, vertebrae and ribs

SL= standard body length, Imm= immature, Mat= mature, Unk= unknown; country names according to ISO abbreviations.



Figure 6a. Deep cut on the anterior insertion of the dorsal fin in an inshore *Tursiops truncatus* (PBD-007) from the Bay of Paracas (Peru).



Figure 6b. Remains of a nylon twines encroached in a large scar on the anterior basis of the dorsal fin and healing lesion on the tailstock of an adult *Sotalia guianensis* (SEP-005) from Sepetiba Bay (Brazil).



Figure 6c. Half-severed dorsal fin together with a large scar from a shark bite in a free-ranging *Sotalia guianensis* (SEP-015) from Sepetiba Bay (Brazil)

Table 6. Prevalence of osteopathologies and malformations in small cetaceans from Peru, Brazil and Venezuela.

AREA AND SPECIES SPECIES	HABITAT	SAMPLING PERIOD	SPECIMENS	BONE REMAINS	ALL LESIONS ^a	LYTIC LESIONS	DEGENERATIVE DISEASES ^b	TRAUMAS & FRACTURES	CONGENITAL MALFORMATIONS
Peru									
<i>Delphinus capensis</i>	Offshore/neritic	1985-2000	By-caught	103 skulls & calvariae	36.8%	32%	3.9%	1.9%	2.9%
<i>Lagenorhynchus obscurus</i>	Offshore/neritic	1984-2001	By-caught & stranded	46 skulls & calvariae	28.3%	15.2%	2.2%	4.3%	8.7%
<i>Phocoena spinipinnis</i>	Inshore/neritic	1985-1999	By-caught	37 skulls & calvariae	5.4%	5.4%	0%	0%	0%
<i>Tursiops truncatus</i>	Inshore/neritic	1984-2000	By-caught & stranded	26 skulls & calvariae	38.5%	26.9%	15.4%	7.7%	3.8%
<i>Tursiops truncatus</i>	Offshore/pelagic	1984-2000	By-caught & stranded	42 skulls & calvariae	69.1%	42.9%	31%	7.1%	0%
Brazil									
<i>Sotalia guianensis</i>	Inshore/estuarine	1987-1998	By-caught & stranded	53 skulls	30.2%	18.9%	1.9%	5.7%	7.6%
<i>Sotalia guianensis</i>	Inshore/estuarine	1987-1998	By-caught & stranded	53 axial skeletons	51%	7.6%	0% ^c	47.2%	9.4%
<i>Sotalia guianensis</i>	Inshore/estuarine	2001-2006	By-caught & stranded	31 axial skeletons	48.4%	3.2%	0%	3.2%	48.4%
<i>Tursiops truncatus</i>	Inshore & offshore	2001-2005	By-caught & stranded	8 skulls	37.5%	25%	12.5%	0%	0%
<i>Tursiops truncatus</i>	Inshore & offshore	2001-2005	By-caught & stranded	8 axial skeletons	25%	12.5%	0%	12.5%	12.5%
Venezuela									
<i>Sotalia guianensis</i>	Inshore/estuarine	1991-2002	By-caught & stranded	46 skulls	15.2%	10.9%	2.2%	4.4%	0%

^a some specimens had several kind of lesions; ^b including only hyperostosis and AS; ^c cases of other degenerative diseases were reported in Frago (2001).

These injuries may have been inflicted by violent conspecific or interspecific interactions (see *e.g.* Jepson and Baker, 1998), fishery interactions or resulted from congenital defects and functional stress (Fragoso, 2001; Laeta *et al.*, 2006²⁰). In the 1987-1998 sample, lesions of the skull associated with remains of fishing gear were seen in two mature dolphins. Finally, the palatine of a juvenile male was perforated as from a sharp fish spine or bone. An adult male *T. truncatus* (GEMM-081) live-stranded in RJ in 2005 showed healed and non-healed fractures of several ribs (both left and right) and of the neural process of the fourth and fifth thoracic vertebrae. These traumata were also likely caused by conspecific, interspecific or fishery interactions.

PERU. Among four species, prevalence of fractures and traumas in by-caught specimens varied from 0% in *P. spinipinnis* to 7.7% in inshore *T. truncatus* (Table 6). Healed or non-healed fractures were encountered in the mandibles of one *L. obscurus*, one *D. capensis*, two inshore *T. truncatus* and three offshore *T. truncatus*, all adults (Figure 9a), either from the impact of fishing gear or from violent conspecific or interspecific interactions. In two other cases the injuries were definitely anthropogenic. A *L. obscurus* was shot in the head and the impact of the bullet was seen in the right maxillary, right pterygoid and left mandible. Two holes (diameters 15 and 5mm) with irregular edges, likely inflicted by an unidentified piercing object, perforated the occipital bone close to the left condyle in a mature male *D. capensis* (Van Bresseem *et al.*, 2006b). The non-healed fracture in the mandible of a mature *T. truncatus* may also have had an anthropogenic origin (Figure 9a).

VENEZUELA. Perimortem traumata, possibly inflicted by a piercing or smashing object were observed in the skull of two immature *S. guianensis* found in Falcón (1991) and Zulia (2002) (Tables 5 and 6).

URUGUAY. A cranially mature female Cuvier's beaked whale (*Z. cavirostris*) stranded in Laguna Garzon at an indeterminate date during 1998-2000 had healed fractures in the two posterior lumbar vertebrae, two anterior caudal vertebrae, and healing complete fractures in three ribs and the right mandible. Such findings of multiple fractures would be consistent with a collision with a large vessel. A cranially mature *P. crassidens* found in Laguna Garzon in the same period had fractures in two ribs.

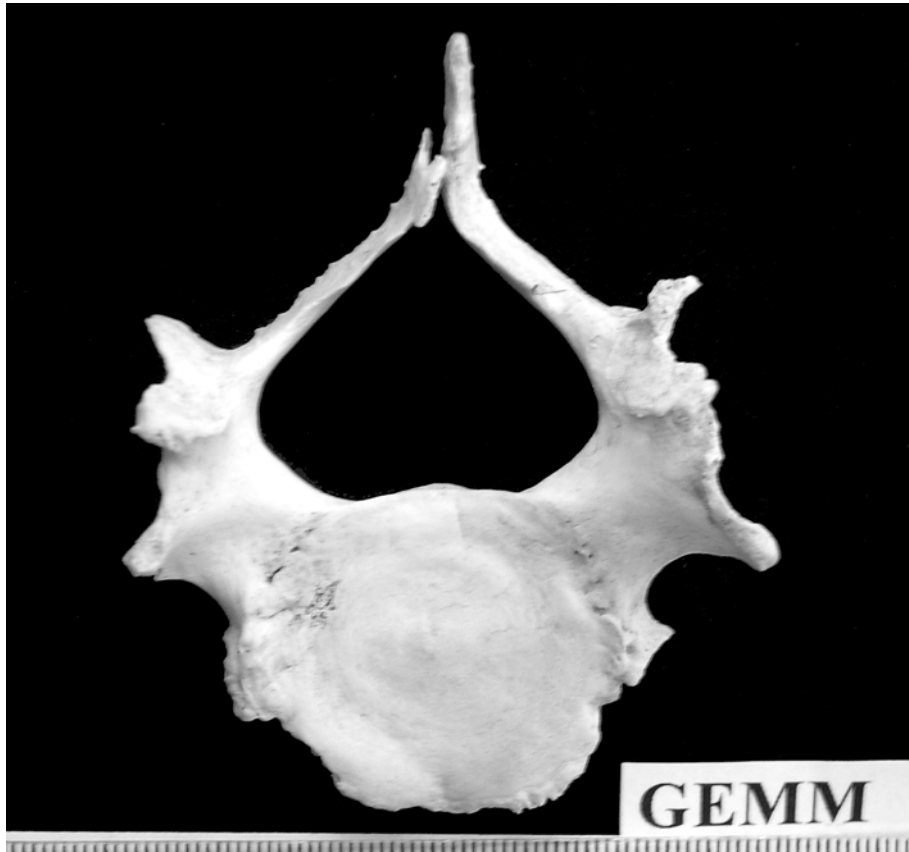

Figure 7. Congenital malformations in the seventh cervical vertebra of a *Sotalia guianensis* (GEMM-068) from northern Brazil.



Figure 8. Complete skull malformation in an adult *Lagenorhynchus obscurus* (MFB-667) (Peru).

➤Lytic lesions

OSTEOMYELITIS AND OSTEOLYSIS. Osteomyelitis is characterized by non-specific acute or chronic, localized or generalized, bone infection accompanied by bone destruction or dissolution (osteolysis) and new bone formation. Prevalence of such lesions is given in Table 7. In *S. guianensis* from Brazil osteomyelitis and osteolysis were diagnosed in the stylohyoid (one case), the occipital condyles and atlas-axis block (one case), the scapulae (two cases) and in the lumbar and caudal vertebrae (two cases). In *S. guianensis* from Venezuela, osteomyelitis and osteolysis were detected only in the maxillaries and mandibles (Figure 9b). In Peruvian cetaceans, they

mostly affected the mandibles, maxillaries and premaxillaries (Figure 10a). In one *D. capensis*, osteomyelitis also affected the pterygoid and palatine. An offshore *T. truncatus* presented extensive osteolysis in the left mandibular ramus (Figure 9a). In both dolphins, the osteolytic lesions may have been caused by a trauma. Some osteolysis was observed in both scapulae of a *Z. cavirostris* (Figure 10b) stranded in Laguna Garzon (Uruguay) and in an immature, female inshore *T. truncatus* found along the coast of RJ in 2001. Possible osteomyelitis was reported in a caudal vertebra of a *P. crassidens* stranded in Laguna Garzon that also suffered extensive hyperostosis and ankylosing spondylitis.

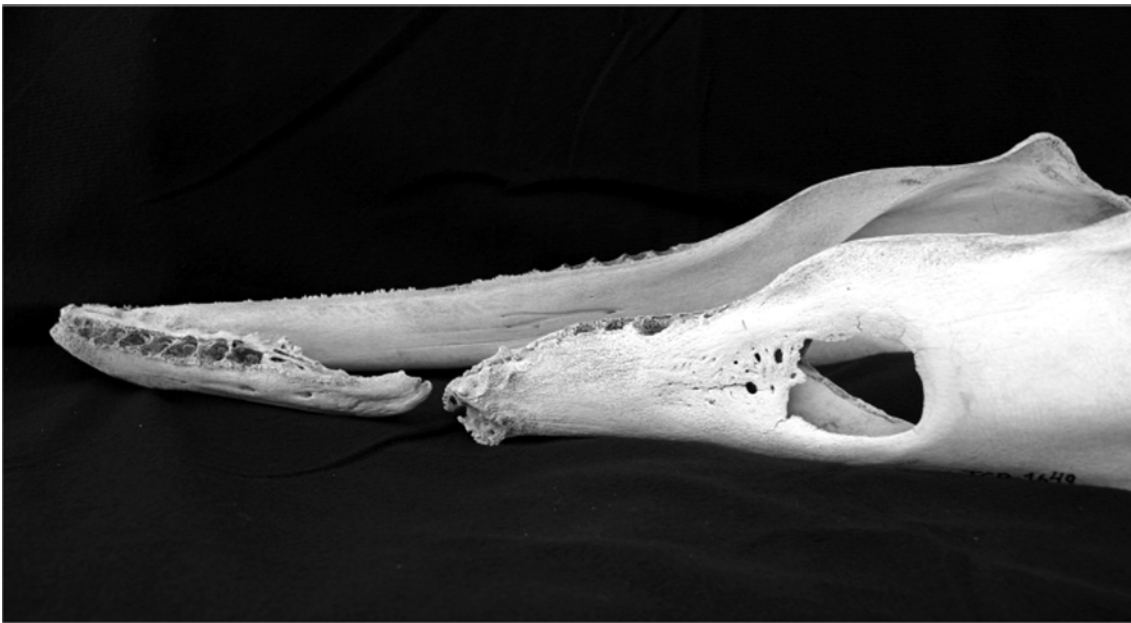


Figure 9a. Complete fracture of the left mandible together with a large, oval lytic lesion in an adult offshore *Tursiops truncatus* (JCR-1649) (Peru).

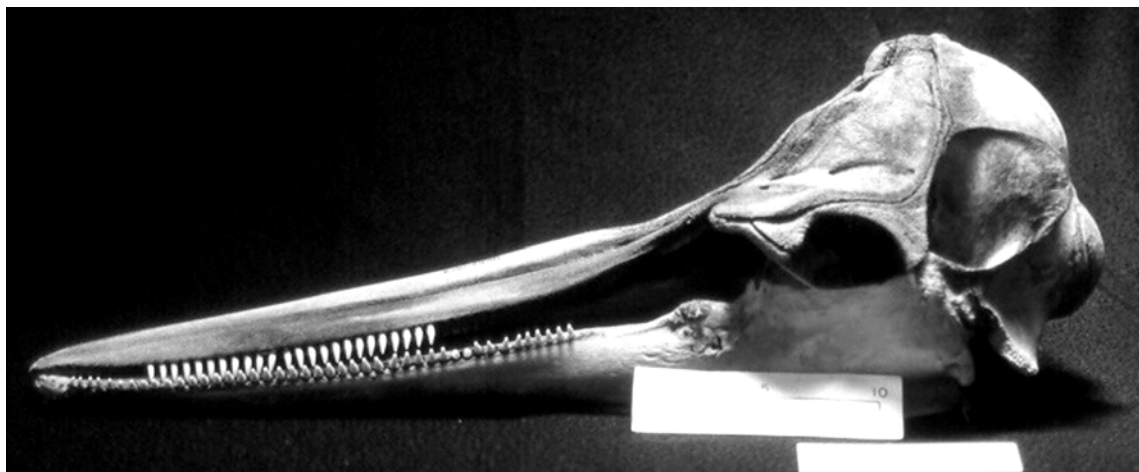


Figure 9b. Osteolysis and osteomyelitis on the right mandible of a *Sotalia guianensis* (EBRG-21069) from Venezuela.

Table 7. Prevalence of lytic lesions in small odontocetes from Peru, Brazil and Venezuela.

AREA AND SPECIES	HABITAT	SAMPLING PERIOD	BONE REMAINS	N	CRASSICAUDA SPP.	LYTIC LESIONS		
						OSTEOMYELITIS	OSTEOLYSIS	PLD
Peru								
<i>Delphinus capensis</i>	Offshore/neritic	1985-2000	Skulls	103	26.5% ^a	1.9%	4.9%	1%
<i>Lagenorhynchus obscurus</i>	Offshore/neritic	1984-2001	Skulls	46	4.4%	0%	2.1%	8.7%
<i>Phocoena spinipinnis</i>	Inshore/neritic	1985-1999	Skulls	37	0%	2.7%	5.4%	2.7%
<i>Tursiops truncatus</i>	Inshore/neritic	1984-2000	Skulls	26	7.7%	7.7%	7.7%	15.4%
<i>Tursiops truncatus</i>	Offshore/pelagic	1984-2000	Skulls	42	26.2%	4.8%	9.5%	16.7% ^b
Brazil								
<i>Sotalia guianensis</i>	Inshore/estuarine	1987-1998	Skulls	53	1.9% ^c	1.9%	0%	15.1%
<i>Sotalia guianensis</i>	Inshore/estuarine	1987-1998	Axial skeleton	53	-	7.6%	0%	-
<i>Sotalia guianensis</i>	Inshore/estuarine	2001-2006	Axial skeletons	31	-	3.2%	0%	-
<i>Tursiops truncatus</i>	Inshore & offshore	2001-2005	Skulls	8	25%	0%	0%	indet.
<i>Tursiops truncatus</i>	Inshore & offshore	2001-2005	Skeletons	8	-	12.5%	12.5%	-
Venezuela								
<i>Sotalia guianensis</i>	Inshore/estuarine	1991-2003	Skulls	46	0%	2.2%	6.5%	10.9%

N = total number of specimens, PLD= periodontal lytic disease; indet.=indeterminate, ^aN =98; ^b this percentage may be an underestimate; ^c possible *Crassicauda* spp. infestation in one *Sotalia guianensis*.

**Figure 10a.** Osteomyelitis in the left mandible of a mature *Delphinus capensis* (KVV-2400) (Peru).

PERIODONTAL LYSIS. Periodontal lysis (Table 7), presumably caused by miscellaneous local infections in mature and immature odontocetes (Figure 11) represented from 6.1% (*D. capensis*, Peru) to 100% (*P. spinipinnis*, Peru) of the cases of osteolysis and osteomyelitis observed in skulls from Peru, Brazil and Venezuela (Table 7).

CRASSICAUDIASIS. Crassicaudiasis was detected in all species except in *P. spinipinnis* from Peru and *S.*

guianensis from Venezuela (Figure 12; Table 7). Possible *Crassicauda* lesions were also seen in the pterygoids of a mature *S. guianensis* from northern RJ. The pterygoid bones were most frequently affected in all species except in *L. obscurus* where only the alisphenoid, basioccipital and frontal were damaged. Prevalence of *Crassicauda* spp. lesions varied significantly ($\chi^2 = 10.46$, $df = 1$, $P = 0.0012$) according to the species and ecotypes, being higher in *D. capensis* and offshore *T. truncatus* from Peru (Table 7).

Figure 10b. Osteolysis in the scapula of a mature *Ziphius cavirostris* (ZCAV-SN) (Uruguay).

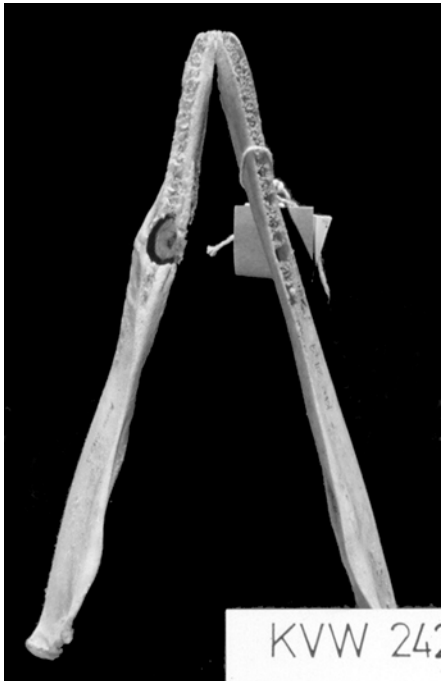
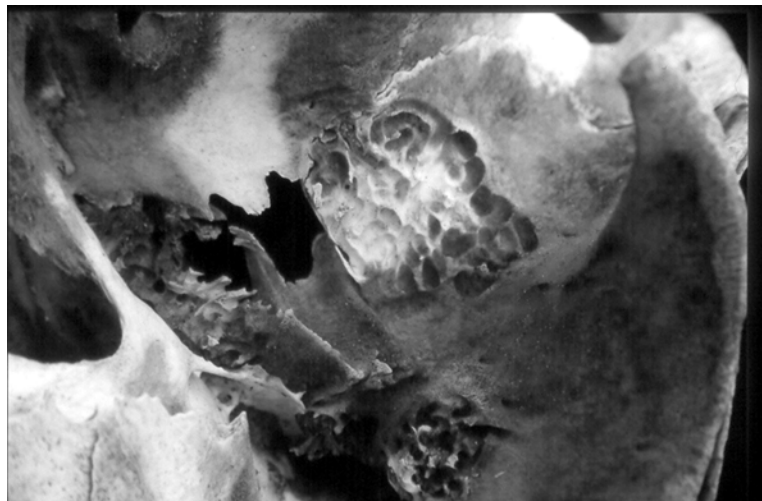


Figure 11. Periodontal lytic disease in a mature *Phocoena spinipinnis* (KVV-2427) (Peru).

Figure 12. *Crassicauda* spp. lesions in the skull of an immature offshore *Tursiops truncatus* (DMI-186) (Peru).



In *D. capensis*, prevalence did not vary significantly (Fisher's; $P = 0.8$) between cranially adult females (25%, $n = 8$) and males (19.4%, $n = 31$), allowing pooling of sexes. Prevalence of *Crassicauda* cranial bone damage was similar ($\chi^2 = 0.177$, $df = 1$, $p = 0.67$) in cranially immature (22.7%, $n = 22$) and adult (27.3%, $n = 66$) dolphins (Van Bressem *et al.*, 2006b). The same may be true in offshore *T. truncatus* but sub-samples were too small to verify this hypothesis (Table 8).

➤ Degenerative bone diseases

Degenerative bone diseases including hyperostosis and ankylosing spondylitis were seen in all species examined with the exception of *P. spinipinnis*. They were especially frequent (31%) in offshore *T. truncatus* from Peruvian waters (Table 6).

HYPEROSTOSIS. Hyperostosis, a condition characterized by

diffuse or localised bone overgrowth, sometimes concurrent with bone rarefaction, was diagnosed in skulls from inshore and offshore *T. truncatus* (Figure 13a), *L. obscurus* and *D. capensis* from Peru as well as in the skull of an inshore *T. truncatus* from northern RJ and on the vertebrae of a *P. crassidens* from Uruguay. In Peruvian *T. truncatus*, this condition always affected the occipital bone and less frequently the nasals, maxillaries and frontal bone. Hyperostosis was benign or severe, affecting the whole skull. Prevalence of this condition in four sub-samples of offshore *T. truncatus* is given in Table 8. In these dolphins, prevalence of hyperostosis seemed to be higher in mature males than in immature males and mature females. However, significance could not be statistically tested due to small sample size. Hyperostosis occurred in three immature and one mature inshore *T. truncatus* of unknown sex.

Table 8. Prevalence of *Crassicauda* spp., hyperostosis and ankylosing spondylitis in four sub-samples of offshore bottlenose dolphins from Peru.

		CRASSICAUDA SPP. LESIONS			HYPEROSTOSIS			ANKYLOSING SPONDYLITIS		
		N	NPOS	PREV	N	NPOS	PREV	N	NPOS	PREV
♂	Immature	5	2	40%	5	1	20%	5	1	20%
	Mature	12	4	33.3%	12	8	66.7%	12	2	16.7%
♀	Immature	5	1	20%	5	1	20%	5	0	0%
	Mature	4	0	0%	4	1	25%	4	1	25%

N = total number of specimens; Npos = number of positive; Prev = prevalence.

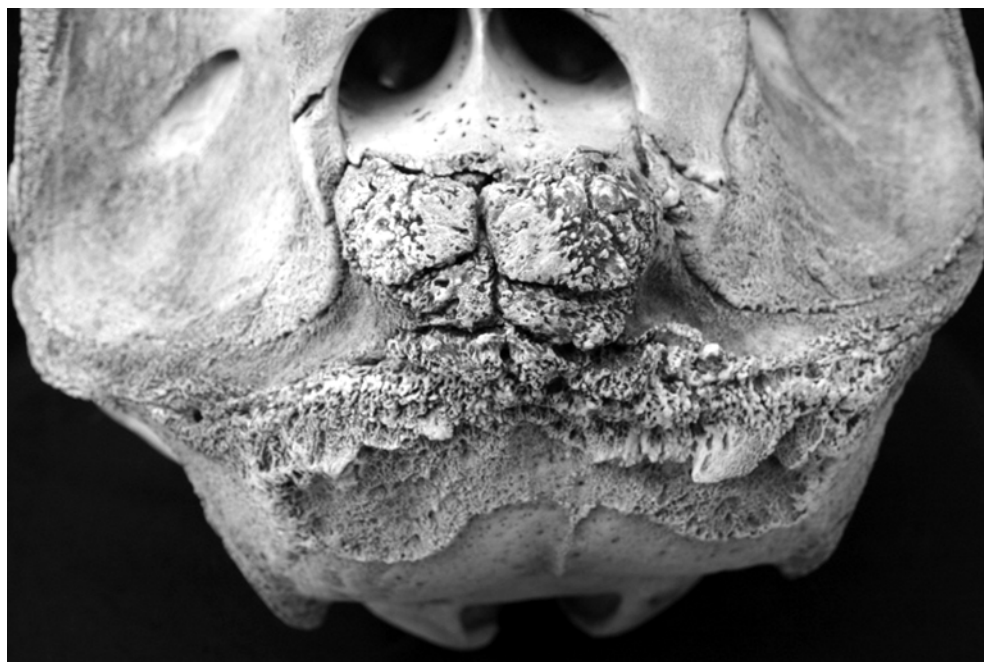

Figure 13a. Hyperostosis in a mature offshore *Tursiops truncatus* (JCR-1649) (Peru).

ANKYLOSING SPONDYLITIS. Ankylosing spondylitis (AS) is a syndrome including new bone formation, loss of bone density and often resulting in the fusion of two or more vertebrae or the atlas ankylosing with the occipital bone, as well as other abnormal ankylosing processes (Sweeny *et al.*, 2005). It was encountered in both *T. truncatus* ecotypes from Peruvian waters (Figure 13b) with prevalences of 3.9% and 9.5% in, respectively, 26 inshore and 42 offshore dolphins. All affected specimens also suffered hyperostosis. The only inshore bottlenose dolphin with AS was an immature (176 cm) individual of unknown sex. All its cervical vertebrae were ankylosed into one block and the atlas had started to fuse with the occipital. Possible AS was also observed in the caudal vertebrae of an immature *D. delphis* and the lumbar vertebrae of a mature *T. truncatus* stranded in the northern Gulf of Guayaquil (Ecuador) in 1998-1999 as well as in three caudal vertebrae of a *P. crassidens* from Uruguay.

Discussion

In this paper we documented and reviewed skin and skeletal diseases, congenital malformations and externally visible traumata, many apparently due to encounters with fishing gear and boats, in small cetaceans from SA waters.

Tattoo skin disease is caused by poxviruses that belong to a recently discovered genus of Chordopoxvirinae, but which have a common, most immediate ancestor with terrestrial poxviruses of the genus *Orthopoxvirus* (Flom and Houk, 1979; Geraci *et al.*, 1979; Bracht *et al.*, 2006). These viruses are thought to induce humoral immunity that may protect calves from the disease via colostrum ingestion (Smith *et al.*, 1983; Van Bresseem and Van Waerebeek, 1996). TSD was known only in odontocetes until 2006 when it was first reported from a bowhead whale (*Balaena mysticetus*) (Bracht *et al.*, 2006). Here we report for the first

time on the presence of TSD in *D. delphis* from Ecuador, *P. spininnipis*, *T. truncatus* and *C. eutropia* from Chile, *C. commersonii* from Argentina and *S. guianensis* from Brazil, thus extending the geographic area and the number of species susceptible to this disease. It is the first time that TSD is encountered in the SW Atlantic. With the exception of Peruvian dolphins and porpoises, the epizootiological status of TSD in SA small cetaceans is unknown and should be explored further. Though cetacean poxviruses apparently do not cause high mortality when endemic (Van Bresseem *et al.*, 1999), they could represent a significant threat to naive populations.

The appearance of velvety, sometimes ulcerative, skin marks as well as of large, rounded lesions in dolphins from Peru, Chile, Argentina and Brazil, we suggest, may be related to poor water quality. The bay of Paracas is heavily contaminated by organic material (phosphorus and organic nitrogen) released by fish-meal factories and surrounding towns, resulting in severe water eutrophication (PNUMA/CONAM, 2006). The factories also release caustic soda used to clean the machines (CPPS, 1998). In addition, ballast water from the numerous cargo ships transporting gas in the bay as a consequence of the CAMISEA project may introduce alien micro-organisms that could significantly harm ecosystems (Ruiz *et al.*, 2000; PNUMA/CONAM, 2006; Drake *et al.*, 2007). Chile's southern fjords are home to large numbers of salmon fish farms that continue to expand, heavily use prophylactic antibiotics that select antibiotic resistance in pathogenic bacteria and release biological and chemical contaminants directly into the ocean (Moore and Wieting, 1999; Kemper *et al.*, 2003; Cabello, 2004; 2006). Interestingly, skin lesions were also reported from an appreciable number of blue whales (*Balaenoptera musculus*) off the northwestern coast of Isla Grande de Chiloé (Brownell *et al.*, 2007) and Chañaral Island (G. P. Sanino, unpublished data), Chile.



Figure 13b. Ankylosing spondylitis in a mature offshore *Tursiops truncatus* (KVW-1047) (Peru). All cervicals are fused into a single block, which is fused to the occipital.

Sepetiba Bay in Brazil is home to two large ports and is characterized by chemical and organic pollution as well as water eutrophication (Copeland *et al.*, 2003; Molisani *et al.*, 2004).

Lobomycosis (or lacaziosis) is caused by a yeast-like organism known as *Lacazia loboi* (Taborda *et al.*, 1999) (syn. *Loboa loboi*; Caldwell *et al.*, 1975). It naturally affects humans and dolphins (*T. truncatus* and *S. guianensis*). In humans, it is a self-limited, chronic fungal infection of the skin endemic in rural regions in South and Central America. The natural reservoir of *L. loboi* is unknown but soil and vegetation seem to be likely sources of infection (Honda *et al.*, 2007). Patients with lobomycosis may have immunoregulatory disturbances that could be responsible for the lack of pathogen containment (Vilani-Moreno *et al.*, 2005; Honda *et al.*, 2007). In *T. truncatus* from the southern part of the Indian River Lagoon, Florida, the disease was associated with an impaired immune function possibly caused by anthropogenic factors. Variation in salinity and water temperature may also play a role (Reif *et al.*, 2006). During the present study lobomycosis-like disease was only seen in inshore populations of *T. truncatus*. Those from Colombia, Ecuador and southern Brazil (Santa Catarina) inhabited waters of low salinity and relatively high temperature situated close to mangroves and estuaries. All affected *T. truncatus* inhabited waters surrounding large ports and cities and, in the case of Guayaquil, also harbouring intense shrimp farming activities. Most of these waters are heavily polluted by chemicals and biological contaminants (CPPS, 2000; WHO/UNICEF/WSSCC, 2001; CVC, 2003; UNEP, 2006). It is quite likely that some of these pollutants affect the immune system of inshore dolphins as described for cetaceans elsewhere (Aguilar and Borrell, 1994; Jepson *et al.*, 1999; Smyth *et al.*, 2000). Ballast water from the numerous cargo ships entering SA ports may have contributed to disseminate the yeast to places where it was normally not present. In addition, cities in the region typically discharge untreated wastewater directly into estuaries and oceans. The waters of the Bay of Málaga and surroundings (Colombia), Gulf of Guayaquil (Ecuador), Florianópolis, Laguna and Mampituba rivers (Brazil) and Lima (Peru) contain extremely high levels of fecal coliforms (SDM, 1998; CPPS, 2000; CVC, 2003; Haase *et al.*, 2003²⁸) indicative of organic contamination and considered a major health threat to humans. In Brazil, all cases of lobomycosis and LLD, including the first report in an adult female bottlenose dolphin in 1990 in Laguna (28°30'S, 48°55'W) by Simões-Lopes *et al.* (1993), were recorded between Baía Norte (27°50'S, 48°58'W) and Tramandaí estuary (29°58'S, 50°07'W). It is likely that LLD is endemic in the coastal population of *T. truncatus* from this area. The infection may represent a threat to possibly susceptible *S. guianensis* (de Vries and Laarman, 1973; Flores *et al.*, 2005¹⁸). Though the

organism found in dolphins may not be the same as in humans (Haubold *et al.*, 2000), lobomycosis and LLD may be zoonotic and care should be taken when manipulating affected dolphins (Symmers, 1983). Fishermen work closely to bottlenose dolphins during cooperative mullet fishing in Laguna, Torres and Tramandaí estuary (Simões-Lopes *et al.*, 1998) and may be at risk of infection. Indications are that in Peru LLD is a newly emerging disease in inshore bottlenose dolphins. Further research on the aetiology and epizootiologic trends of skin diseases in small cetaceans from South America is urgently needed, including periodic surveys to assess the presence of cutaneous lesions and the analysis of existing image databases.

External injuries, body traumata and bone fractures caused by interaction with fisheries and boats were seen in inshore and offshore small cetaceans from both SW Atlantic and SE Pacific oceans. Severe traumata due to a variety of fishing devices likely result in secondary mortality of unassessed numbers of escaping but injured dolphins and porpoises. Therefore, total fisheries-related small cetacean mortality must be higher than can be accounted for by the tallying of landed specimens. A number of cases of incisive injuries, dorsal fin mutilation and bone fractures are the result of boat collisions, especially propeller hits, however other potential sources like fishing lines and post-mortem damage on carcasses must be excluded (Van Waerebeek *et al.*, 2007). Boat collisions and net entanglements likely cause great stress in surviving animals. Chronic high levels of stress hormones may depress the immune system and favour the development of infectious diseases as well as damage the circulatory system and kidneys (*e.g.* Van Bresseem *et al.*, 1994; Cowan and Curry, 2002).

Various osteolytic lesions of the skull were common in several species of dolphins and in Burmeister's porpoises in Peru, Brazil and Venezuela. Periodontitis and dental diseases, impact or piercing traumata as well as *Crassicauda* spp. infestation were firmly or tentatively diagnosed as the origin for a high percentage of these conditions. In *P. spinipinnis*, periodontal and dental diseases were thought responsible for all the lytic injuries. These diseases are likely a consequence of tooth decay, infection and loss (De Smet, 1977). The loss of a large number of teeth with resulting damage to the alveoli and, eventually, lysis of surrounding bone tissue may lead to considerable pain in the affected animals. Post-traumatic osteolysis has been reported in humans (Ryan and Munk, 2004) and is thought to have been responsible for lysis found in the mandibles of a *S. guianensis* (Venezuela) and an offshore *T. truncatus* (Peru) examined during this study. Adult roundworms *Crassicauda* spp. infest the cranial sinuses and produce the typical, apparently irreversible, perforating lytic bone lesions with a basket-like appearance that often deform pterygoids (Raga *et al.*, 1982; Dailey, 1985).

²⁸ Haase, J., Stringhini, M.H., Silva, M.L.B.C., Rodrigues, M.L.K. and Koch, S.M.V. (2003) *Qualidade das águas superficiais do litoral norte e médio do Rio Grande do Sul*. Pages 1-17 in 22^o Congresso Brasileiro de Engenharia Sanitária e Ambiental, 14-19 September, 2003, Joinville, SC, Brazil.

They were entirely absent in Peruvian *P. spinipinnis*. In the other species the highest prevalence was observed in the offshore/pelagic stocks, pointing to a prey relationship. Interestingly, in offshore *T. truncatus* and in *D. capensis* from Peru, mature and immature specimens were equally affected. However, the primary questions that need to be answered before differential age-related mortality can be confidently evaluated from skulls are whether the bone lesions remain extant long after the nematodes have died, and whether re-infection is likely. In pantropical spotted dolphins (*Stenella attenuata*) from the Eastern Tropical Pacific, prevalence was higher in younger animals, which was attributed to mortality caused by *Crassicauda* spp. infestation in young dolphins (Perrin and Powers, 1980). However, if most infested juveniles recovered, build some level of immunity and cranial lesions healed, it would also be consistent with findings. The osteomyelitic lesions observed in this study probably have a bacterial origin as in other mammals (Bubenik, 2005) though protozoans and fungi cannot be excluded. *Brucellae* are known to circulate among Peruvian *D. capensis* and may have caused orchitis and vertebral lesions in at least one specimen (Van Bresseem *et al.*, 2006b).

Degenerative diseases including hyperostosis and ankylosing spondylitis were especially prevalent in offshore *T. truncatus* from Peru, possibly related to deep-water feeding habits. There was some indication that hyperostosis may occur more frequently in adult males than in others but larger samples are required for testing. If confirmed, the hypothesis that the disease might be related to physiological (hyperbaric) stress associated with feeding at greater depths in adult males than in immatures and females would deserve further study. Hyperostosis seems to be linked to the development of ankylosing spondylitis. Prevalence of AS was similar in mature and immature male offshore *T. truncatus*. The only inshore dolphin with AS was a young immature. The aetiology of AS in humans is still poorly understood, but a strong genetic influence exists and approximately 90-95% of patients with AS have the tissue antigen human leukocyte antigen B27 (Dougados, 2005). Unknown environmental factors (bacterial infection in humans) may trigger the development of AS in individuals genetically predisposed. Hyperbaric stress related to deep diving may represent one of those factors in offshore *T. truncatus* and other species with similar feeding habits. Prevalence of AS was 21% in 52 long-finned pilot whales (*Globicephala melas*) from the Northwest Atlantic (Sweeny *et al.*, 2005). Degenerative diseases called 'spondylitis' and 'spondylosis deformans' were previously described in small odontocetes (reviewed by Kompanje, 1995a,b).

The high prevalence of congenital bone malformations in *S. guianensis* from northern RJ is of great concern and likely indicates a genetic bottleneck in this population. The malformations possibly facilitated the occurrence of fractures seen in the vertebrae of this species (Fragoso,

2001; Laeta *et al.*, 2006²⁰; this paper). At least 25% of the 167 photo-identified adult *S. guianensis* from Sepetiba Bay presented infectious skin diseases, body deformations, emaciation and traumata caused by boat collisions and non-lethal entanglement in gillnets. The injuries likely result in high stress levels and secondary mortality which goes unaccounted for. In addition, in both southern and northern RJ, coastal waters are heavily contaminated by industrial and domestic wastes (FEEMA, 2007). Altogether findings indicate that this *S. guianensis* population is in poor health and underscore the need to closely monitor health status including their genetic variability and to improve and enforce conservation measures.

We conclude that odontocetes from SA waters are affected by a variety of acquired, congenital, traumatic, infectious and parasitic diseases. Some of these are severe and bound to impair normal vital functions and behaviour. Interactions with artisanal and industrial fisheries and, to a lesser degree, boat collisions, are an important cause of debilitating physical traumata in several populations. The feasibility of applying fishing gear modifications and other potential bycatch mitigation measures, including regulatory instruments, should be re-evaluated in South America as one of the most relevant issues for the enhanced conservation of marine mammal populations. In addition, aquaculture, fish factories, untreated wastewater, ballast water as well as chemical pollution are believed to play a significant role in the deterioration of modal cetacean population health and in facilitating the emergence of new diseases. Further research to establish cause-effect relationships is required.

Acknowledgements

Field work in Peru from 1985 onwards and data analysis were supported by many organisations, the principal sponsors including the Belgian Agency for Developing Aid, Cetacean Society International, Gesellschaft zur Rettung der Delphine, Gesellschaft zum Schutz der Meeressäugetiere, IFAW, IUCN/Cetacean Specialist Group, Leopold III Fonds voor Natuuronderzoek en Natuurbehoud, United Nations Environment Programme (UNEP) and Whale and Dolphin Conservation Society. The data on dolphins from northern Rio de Janeiro were collected during the 'Projeto Mamíferos e Quelônios Marinhos' developed and sponsored by 'Gerência de Avaliação e Monitoramento Ambiental do Centro de Pesquisas de PETROBRÁS'. Ana Paula Di Benedetto, Ignacio Moreno and Paulo Flores were supported by fellowships of the 'Conselho Nacional de Desenvolvimento Científico e Tecnológico - CNPq (Proc no. 300322/2003-8, Proc no. 140660/2004-6 and Proc no. 146609/1999-9, respectively). Fundación Yubarta was supported by the 'Corporación Ecofondo'. We kindly thank Silvana Gomes, who helped with carcass collection in northern

RJ, Larissa Heinzemann, Lilian Hoffmann and Sue Bridi Nakashima for helping with the collection of the stranded dolphin in Tramandaí River, as well as Mauro Borba (Faculdade de Veterinária/UFRGS) for the histological diagnostic of lobomycosis. We also thank Pablo Echegaray, director del Museo del Mar de Maldonado, Uruguay, Richard Möller for his help with specimens from Uruguay, Lilián Flórez-González, Patricia Falk-Fernández, Angela Recalde, Elizabeth Hernández, Juan Capella and Wilfredo Henao, Francisco Javier Álvarez and Rafael Martan for their help in collecting data on LLD in Colombia, Augusto Carrillo for images of specimen JBJ SF 05-03, Francisco Bisbal and Javier Sánchez for providing access to samples under their custody in the EBRG Museum, Dr Víctor Bermúdez for his advice on diseases of Venezuelan small cetaceans and Martin Frixione for the photographs of *C. commersonii*. We gratefully acknowledge Dr J. A. Raga and an anonymous reviewer for their comments on the manuscript.

References

- AGUILAR, A. AND BORRELL, A. (1994) Abnormally high polychlorinated biphenyl levels in striped dolphins (*Stenella coeruleoalba*) affected by the 1990-1992 Mediterranean epizootic. *Science of the Total Environment* 154: 237-247.
- BOLAÑOS-JIMENEZ, J., CAMPO, M.A. AND GONZÁLEZ-FERNÁNDEZ. (1998) Estado actual de los cetáceos de las costas del Estado Aragua. Serie Informes Técnicos, Dirección General de Fauna/IT/386, Ministerio del Ambiente y de los Recursos Naturales, Caracas, Venezuela.
- BRACHT, A.J., BRUDEK, R.L., EWING, R.Y., MANIRE, C.A., BUREK, K.A., ROSA, C., BECKMEN, K.B., MARUNIAK, J.E AND ROMERO, C.H. (2006) Genetic identification of novel poxviruses of cetaceans and pinnipeds. *Archives of Virology* 151: 423-438.
- BROWNELL, R. L. JR., CARLSON, C.A., GALLETI VERNAZZANI, B. AND CABRERA, E. (2007) Skin lesions on blue whales off Southern Chile: possible conservation implications? Paper SC/59/SH21 presented to the IWC Scientific Committee, May 2007 (unpublished).
- BUBENIK, L.J. (2005) Infections of the skeletal system. *Veterinary Clinics of North America: Small Animal Practice* 35(5): 1093-1109.
- CABELLO, F.C. (2004) Antibióticos y acuicultura en Chile: consecuencias para la salud humana y animal. *Revista de Medicina de Chile* 132: 1001-1006.
- CABELLO, F.C. (2006) Heavy use of prophylactic antibiotics in aquaculture: a growing problem for human and animal health and for the environment. *Environmental Microbiology* 8: 1137-1144.
- CALDWELL, D.K., CALDWELL, M.C., WOODARD, J.C., AJELLO, L., KAPLAN, W. AND MCLURE, H.M. (1975) Lobomycosis as a disease of the Atlantic bottle-nosed dolphin (*Tursiops truncatus* Montagu, 1821). *American Journal of Tropical Medicine* 24: 105-114.
- COMISION PERMANENTE DEL PACIFICO SUR - CPPS (1988) Estudio piloto para el ordenamiento ambiental del área Pisco Paracas (Ica, Peru), Volumen I: Diagnóstico Ambiental del área de Pisco Paracas. Lima, Peru. 331 pp.
- COMISION PERMANENTE DEL PACIFICO SUR - CPPS (2000) Estado del Medio Ambiente Marino y Costero del Pacífico Sudeste. Quito, Ecuador. 165 pp.
- COPELAND, G., MONTEIRO, T., COUCH, S. AND BORTHWICK, A. (2003) Water quality in Sepetiba Bay, Brazil. *Marine Environment Research* 5: 385-408.
- CORPORACION AUTONOMA REGIONAL DEL VALLE DEL CAUCA-CVC. (2003) Plan de gestión ambiental regional del Valle del Cauca 2002 -2012: Participación con Compromiso. Grupo de Planificación Ambiental y Grupo Archivo Corporativo. Segunda Edición. Cali, Colombia. 264 pp.
- CLARK, L.S., COWAN, D.F. AND PFEIFFER, D.C. (2006) Morphological changes in the Atlantic bottlenose dolphin (*Tursiops truncatus*) adrenal gland associated with chronic stress. *Journal of Comparative Pathology* 135: 208-16.
- COWAN, D. AND CURRY, B. (2002) Histopathological assessment of dolphins necropsied onboard vessels in the eastern tropical pacific tuna fishery, Southwest Fisheries Science Center, National Marine Fisheries Service, NOAA Administrative Report LJ-02-24C. 31 pp.
- CUSICK, P.K. AND BULLOCK, B.C. (1973) Ulcerative dermatitis and pneumonia associated with *Aeromonas hydrophila* infection in the bottle-nosed dolphin. *Journal of the American Veterinary Medicine Association* 163: 578-579.
- DAILEY, M.D. (1985) Diseases of Mammalia: Cetacea. Pages 805-847 in: KINNE, O. (Ed) *Diseases of Marine Mammals*. Vol 4 (2). Biologische Anstalt Helgoland, Hamburg, Germany.
- DE SMET, W.M.A. (1977) The fate of old bottle-nosed dolphins, *Tursiops truncatus*, in nature as revealed by the condition of their skeletons. *Aquatic Mammals* 5(3): 78-86.
- DE VRIES, G.A. AND LAARMAN, J.J. (1973) A case of Lobo's disease in the dolphin *Sotalia guianensis*. *Aquatic Mammals* 1: 26-33.
- DOUGADOS, M. (2005) Ankylosing spondylitis. Orphanet Encyclopedia. www.orfa.net/data/patho/GB/uk-as.pdf.
- DRAKE, L., DOBLIN, M.A, DOBBS, F.C. (2007) Potential microbial bioinvasions via ships' ballast water, sediment, and biofilm. *Marine Pollution Bulletin* 55: 333-341
- FEEMA - FUNDAÇÃO ESTADUAL DE ENGENHARIA E MEIO AMBIENTE (2007) Rio Paraíba do Sul. Available at: <http://www.feema.rj.gov.br/bacia-rio-paraiba-sul.asp?cat=75> Accessed on 26 Mar. 2007.
- FÉLIX, F. (1997) Organization and social structure of the bottlenose dolphin *Tursiops truncatus* in the Gulf of Guayaquil, Ecuador. *Aquatic Mammals* 23: 1-16.
- FLOM, J.O. AND HOUK, E.J. (1979) Morphologic evidence of poxvirus in 'tattoo' lesions from captive bottlenosed dolphins. *Journal of Wildlife Diseases* 15: 593-596.
- FLORES, P.A.C. & FONTOURA, N.F. (2006) Ecology of marine tucuxi, *Sotalia guianensis*, and bottlenose dolphin, *Tursiops truncatus*, in Baía Norte, Santa Catarina state, southern Brazil. *Latin American Journal of Aquatic Mammals* 5: 105-115.
- FRAGOSO, A.B.L. (2001) *Alterações morfológicas e patológicas em esqueletos de boto-cinza Sotalia fluviatilis (Gervais, 1853) do litoral do estado do Rio de Janeiro*. MSc Thesis, Universidade Federal do Rio de Janeiro, Museu Nacional, Rio de Janeiro, RJ, Brazil. 136 pp.

- GERACI, J.R., HICKS, B.D. AND ST AUBIN, D.J. (1979) Dolphin pox: a skin disease of cetaceans. *Canadian Journal of Comparative Medicine* 43: 399-404.
- GERACI, J.R. AND LOUNSBURY, V.J. (Eds). (1993). *Marine Mammals Ashore, a Field Guide for Strandings*. Texas A&M University Sea Grant College Program, Galveston, TX, USA.
- HAUBOLD, E.M., COOPER, C.R. JR, WEN, J.W., MCGINNIS, M.R. AND COWAN, D.F. (2000) Comparative morphology of *Lacazia loboi* (syn. *Loboa loboi*) in dolphins and humans. *Medical Mycology* 38: 9-14.
- HERZING, D.L. (1997) The natural history of free-ranging Atlantic spotted dolphins (*Stenella frontalis*): age classes, color phases, and female reproduction. *Marine Mammal Science* 13 (4): 575-595.
- HOFFMANN, L.S. (2004) *Um estudo de longa duração de um grupo costeiro de golfinhos Tursiops truncatus (Montagu, 1821) (Cetacea, Delphinidae) no sul do Brasil: aspectos de sua biologia e bioacústica*. Ph.D. Thesis. Universidade Federal do Rio Grande do Sul, Porto Alegre, Brazil. 273 pp.
- HONDA, K., HORNER, K. AND RAUGI, G.J. (2007) Lobomycosis. in FIVENSON, D.P., BUTLER, D.F., CALLEN, J.P., QUIRK, C. AND ELSTON, D.M. (Eds) e-Medicine World Medical Library online: <http://www.emedicine.com/derm/topic832.htm>.
- JEPSON, P. AND BAKER, J.R. (1998) Bottlenosed dolphins (*Tursiops truncatus*) as a possible cause of acute traumatic injuries in porpoises (*Phocoena phocoena*). *Veterinary Record* 28: 614-615.
- JEPSON, P.D., BENNETT, P.M., ALLCHIN, C.R., LAW, R.J., KUIKEN, T., BAKER, J.R., ROGAN, E. AND KIRKWOOD, J.K. (1999) Investigating potential associations between chronic exposure to polychlorinated biphenyls and infectious disease mortality in harbor porpoises from England and Wales. *Science of the Total Environment* 243/244: 339-348.
- KEMPER, C.M., PEMBERTON, D., CAWTHORN, M., HEINRICH, S., MANN, J., WÜRSIG, B., SHAUGHNESSY, P. AND GALES, R. (2003) Aquaculture and marine mammals: Co-existence or Conflict? Pages 209-225. in GALES, N., HINDELL, M. AND KIRKWOOD, R. (Eds) *Marine Mammals: Fisheries, Tourism and Management Issues*. CSIRO, Melbourne, Australia.
- KOMPANJE, E.J.O. (1995a). Differences between spondyloosteomyelitis and spondylitis deformans in small odontocetes based on museum material. *Aquatic Mammals* 21: 199-203.
- KOMPANJE, E.J.O. (1995b). On the occurrence of spondylitis deformans in white-beaked dolphins *Lagenorhynchus albirostris* (Gray, 1846) stranded on the Dutch coast. *Zoologische Mededelingen, Leiden* 69: 231-250.
- MIGAKI, G., VALERIO, M.G., IRVINE, B.A AND GRANER, F.M. (1971) Lobo's disease in an Atlantic bottle-nosed dolphin. *Journal of the American Veterinary Medicine Association* 159: 578-582.
- MOLISANI, M.M., MARINS, R.V., MACHADO, W., PARAQUETTI, H.H.M., BIDONE, E.D. AND LACERDA, L.D. (2004) Environmental changes in Sepetiba Bay, SE Brazil. *Regional Environmental Change* 4: 17-27.
- MONTES-ITURRIZAGA, D. (2003) *Descripción y evaluación de alteraciones anatómicas óseas cráneo-mandibulares en cetáceos odontocetos del mar peruano*. BSc Thesis, National University of San Marcos, Lima, Peru. 86 pp.
- MONTES, D.I., CHAVERA, A.C., VAN BRESSEM, M.-F., PERALES, R.C., FALCÓN, N.P. AND VAN WAEREBEEK, K. (2004) Descripción y evaluación anatómica de lesiones óseas cráneo-mandibulares en cetáceos odontocetos del mar peruano. *Revista de Investigaciones Veterinarias del Perú* 15: 13-24.
- MOORE, K AND WIETING, D. (1999) Marine aquaculture, marine mammals, and marine turtles interaction workshop. 12-13 January 1999, Silver Spring, MD. U.S. Department of Commerce, NOAA Technical Memorandum NMFS-OPR-16, 60 pp.
- NORMAN, S.A., RAVERTY, S., MCELLELLAN, B., PABST, A., KETTEN, D., FLEETWOOD, M., GAYDOS, J.K., NORBERG, B., BARRE, L., COX, T., HANSON, B., AND JEFFRIES, S. (2004) Multidisciplinary investigation of stranded harbor porpoises (*Phocoena phocoena*) in Washington State with an assessment of acoustic trauma as a contributory factor (2 May - 2 June 2003). U.S. Department of Commerce, NOAA Technical Memorandum NMFS-NWR-34, 120 pp.
- OTT, P.H. 2004. Tem boto na pescaria. E não é na rede de pesca. *Ciência Hoje das Crianças* 2-6
- PERRIN, W.F. AND POWERS, J.E. (1980) Role of a nematode in natural mortality of spotted dolphins. *Journal of Wildlife Management* 44: 960-963.
- PNUMA/CONAM (2006) Informe sobre el Estado del Medio Ambiente. GEO Bahía Paracas-Pisco. Lima, Peru. 164 pp.
- RAGA, J.A., CASINOS, A., FILELLA, S. AND RADUAN M.A. (1982) Notes on cetaceans of the Iberian coasts. V. *Crassicauda grampicola* Johnston and Mawson, 1941 (Nematoda) cause of injuries in the pterygoids of some specimens of *Grampus griseus*. *Säugetierkundliche Mitteilungen* 30: 315-318.
- RAMOS, R.M.A., DI BENEDITTO, A.P.M. AND MENDONÇA DE SOUZA, S. (2001) Bone lesions in *Sotalia fluviatilis* (Cetacea) as a consequence of entanglement. Case report. *Brazilian Journal of Veterinary Research and Animal Science* 38: 192-195.
- REIF, J.S., MAZZOIL, M.S., MCCULLOGH, S.D., VARELA, R., GOLDSTEIN, J.D., FAIR, P. AND BOSSART, G.D. (2006) Lobomycosis in Atlantic bottlenose dolphins from the Indian River Lagoon, Florida. *Journal of the American Veterinary Medicine Association* 228: 104-108.
- REYES, J.C. AND VAN WAEREBEEK, K. (1995) Aspects of the biology of Burmeister's porpoise from Peru. *Report of the International Whaling Commission* (special issue 16): 349-364.
- ROSS, P.S.R. (2002) The role of immunotoxic environmental contaminants in facilitating the emergence of infectious diseases in marine mammals. *Human and Ecological Risk Assessment* 8: 277-292.
- RUIZ, G.M., RAWLINGS, T.K., DOBBS, F.C., DRAKE, L.A., MULLADY, T., HUQ, A., AND COLWELL, R.R. (2000) Global spread of microorganisms by ships. *Nature* 408: 49-50.
- RYAN, R.S. AND MUNK, P.L. (2004) Radiology for the surgeon: musculoskeletal case 33. *Canadian Journal of Surgery* 47: 372-373.
- SÁNCHEZ, J., KUBA, L., BERÓN-VERA, B., DANS, S.L., CRESPO, E.A., VAN BRESSEM, M.-F., COSCARELLA, M.A., GARCÍA, N.A., ALONSO, M.K., PEDRAZA, S.N. AND MARIOTTI, P.A. (2002) Uterine adenocarcinoma with generalised metastasis in a bottlenose dolphin *Tursiops truncatus* from northern Patagonia, Argentina. *Diseases of Aquatic Organisms* 48: 155-159.
- SANINO, G.P. AND YAÑEZ, J. (2001) Nueva técnica de video identificación y estimación de tamaño poblacional en cetáceos, aplicada en delfines nariz de botella, *Tursiops truncatus*, de Isla Choros, IV región de Chile. *Boletín del Museo Nacional de Historia Natural, Santiago* 50: 37-63.

- SANINO, G.P., HAMILTON-WEST, C., ROJAS, A., YAÑEZ, J.L. AND VAN WAEREBEEK, K. (2003) Estudios de restos varados de *Delphinus delphis*, y primer registro documentado de *Pneumonia focal abscedativa*, en Chile. *Boletín del Museo Nacional de Historia Natural, Santiago* 52: 103-117.
- SDM (1998) Diagnóstico dos recursos hídricos e organização dos agentes da Bacia Hidrográfica do Rio Tubarão e Complexo Lagunar. Secretaria de Estado do Desenvolvimento Urbano e Meio Ambiente. Florianópolis, SC, Brazil. 163pp. <http://www.comitetubarao.unisul.br/gruperh/meio-ambiente.html>.
- SHANE, S.H. (1990) Behavior and ecology of the bottlenose dolphin at Sanibel Island, Florida. Pages 245-265 in LEATHERWOOD, S. AND REEVES, R.R. (Eds) *The Bottlenose Dolphin*. Academic Press, San Diego, CA, USA.
- SICILIANO, S., HASSEL, L.B., DA COSTA CUENCA, S., MENDONÇA DE SOUZA, S., DITTMAR, K. (in press). A case of osteochondromatosis in an orca (*Orcinus orca*: Cetacea, Delphinidae) of the coast of Rio de Janeiro, Brazil. *Journal of Comparative Pathology*.
- SIMÕES-LOPES, P.C., PAULA, G.S. AND XAVIER, F.M., SCARAMELO, A.C. (1993) First case of lobomycosis in bottlenose dolphin from Southern Brazil. *Marine Mammal Science* 9: 329 - 331.
- SIMÕES-LOPES, P.C., FABIÁN, M.E. AND MENEGHETTI, J.O. (1998) Dolphin interactions with the mullet artisanal fishing from Southern Brazil: a qualitative and quantitative approach. *Revista Brasileira de Zoologia* 15: 709-726.
- SMITH, A.W., SKILLING, D.E. AND RIDGWAY, S.H. (1983). Calicivirus-induced vesicular disease in cetaceans and probable interspecies transmission. *Journal of the American Veterinary Medicine Association* 11: 1223-1225.
- SMYTH, M., BERROW, S., NIXON, E. AND ROGAN, E. (2000) Polychlorinated biphenyls and organochlorines in by-caught harbour porpoises *Phocoena phocoena* and common dolphins *Delphinus delphis* from Irish coastal waters. *Biology and Environment. Proceedings of the Royal Irish Academy* 100B: 85-96.
- SWEENEY, M.M., PRICE, J.M., JONES, G.S., FRENCH, T.W., EARLY, G.A. AND MOORE, M. (2005) Spondylitic changes in long-finned pilot whales (*Globicephala melas*) stranded on Cape Cod, Massachusetts, USA, between 1982 and 2000. *Journal of Wildlife Diseases* 41: 717-727.
- SWINSCOW, T.D.V. (1981) *Statistics at Square One*, 7th ed. British Medical Association, London, United Kingdom.
- SYMMERS, W.S. (1983) A possible case of Lobo's disease acquired in Europe from a bottle-nosed dolphin (*Tursiops truncatus*). *Bulletin de la Société de Pathologie Exotique et de ses Filiales* 76: 777-784.
- TABORDA, P.R., TABORDA, V.A. AND MCGINNINS, M.R. (1999) *Lacazia loboi* gen. Nov., comb., the etiologic agent of Lobomycosis. *Journal of Clinical Microbiology* 37: 2031-2033.
- THRUSFIELD, M. (Ed). (1986). *Veterinary Epidemiology*. Butterworths & Co, London, United Kingdom. 280 pp.
- UNEP. (2006) Permanent Commission for the South Pacific (CPPS). Humboldt Current, GIWA Regional Assessment 64. University of Kalmar, Kalmar, Sweden. 98 pp.
- VAN BRESSEM, M.-F. AND VAN WAEREBEEK, K. (1996) Epidemiology of poxvirus in small cetaceans from the Eastern South Pacific. *Marine Mammal Science* 12: 371-382.
- VAN BRESSEM, M.-F., VAN WAEREBEEK, K., REYES, J.-C., DEKEGEL, D. AND PASTORET, P.-P. (1993) Evidence of poxvirus in dusky dolphin (*Lagenorhynchus obscurus*) and Burmeister's porpoise (*Phocoena spinipinnis*) from coastal Peru. *Journal of Wildlife Diseases* 29: 109-113.
- VAN BRESSEM, M.-F., VAN WAEREBEEK, K., GARCIA-GODOS, A., DEKEGEL, D. AND PASTORET, P.-P. (1994) Herpes-like virus in dusky dolphins, *Lagenorhynchus obscurus*, from coastal Peru. *Marine Mammal Science* 10: 354-359.
- VAN BRESSEM, M.-F., VAN WAEREBEEK, K., PIÉRARD, G. AND DESAINTE, C. (1996) Genital and lingual warts in small cetaceans from coastal Peru. *Diseases of Aquatic Organisms* 26: 1-10.
- VAN BRESSEM, M.-F., VAN WAEREBEEK, K., FLEMMING, M. AND BARRETT, T. (1998) Serological evidence of morbillivirus infection in small cetaceans from the Southeast Pacific. *Veterinary Microbiology* 2: 89-98.
- VAN BRESSEM, M.-F., VAN WAEREBEEK, K. AND RAGA, J.A. (1999) A review of virus infections of cetaceans and the potential impact of morbilliviruses, poxviruses and papillomaviruses on host population dynamics. *Diseases of Aquatic Organisms* 38: 53-65.
- VAN BRESSEM, M.-F., VAN WAEREBEEK, K., SIEBERT, U., WÜNSCHMANN, A., CHÁVEZ-LISAMBART, L. AND REYES, J.C. (2000) Genital diseases in the Peruvian dusky dolphin (*Lagenorhynchus obscurus*). *Journal of Comparative Pathology* 122: 266-277.
- VAN BRESSEM, M.-F., VAN WAEREBEEK, K., RAGA, J.A., GODFROID, J., BREW, S.D. AND MACMILLAN, A.P. (2001a). Serological evidence of *Brucella* species infection in odontocetes from the South Pacific and the Mediterranean. *Veterinary Record* 148: 657-661.
- VAN BRESSEM, M.-F., VAN WAEREBEEK, K., JEPSON, P.D., RAGA, J.A., DUGNAN, P.J., NIELSEN, O., DI BENEDETTO, A.P., SICILIANO, S., RAMOS, R., KANT, W., PEDDEMORS, V., KINOSHITA, R., ROSS, P.S., LOPEZ-FERNANDEZ, A., EVANS, K., CRESPO, E. AND BARRETT, T. (2001b). An insight into the epidemiology of dolphin morbillivirus worldwide. *Veterinary Microbiology* 81: 287-304.
- VAN BRESSEM, M.-F., VAN WAEREBEEK, K., RAGA, J.A., GASPAS, R., DI BENEDETTO, A.P., RAMOS, R. AND SIEBERT, U. (2003a) Tattoo disease of odontocetes as a potential indicator of a degrading or stressful environment: a preliminary report. Document SC/55/EI, International Whaling Commission, Berlin, Germany.
- VAN BRESSEM, M.-F., GASPAS, R. AND J. AZNAR. (2003b) Epidemiology of tattoo skin disease in bottlenose dolphins (*Tursiops truncatus*) from the Sado estuary, Portugal. *Diseases of Aquatic Organisms* 56: 171-179.
- VAN BRESSEM, M.-F., VAN WAEREBEEK, K. AND BENNETT, M. (2006a) Orthopoxvirus neutralising antibodies in small cetaceans from the Southeast Pacific. *The Latin American Journal of Aquatic Mammals* 5(1): 49-54.
- VAN BRESSEM, M.-F., VAN WAEREBEEK, K., MONTES, D., KENNEDY, S., REYES J.C., GARCIA-GODOS, A.I., ONTON-SILVA, K. AND ALFARO-SHIGUETO, J. (2006b) Diseases, lesions and malformations in the long-beaked common dolphin (*Delphinus capensis*) from the Southeast Pacific. *Diseases of Aquatic Organisms* 68: 149-165.
- VAN BRESSEM, M.-F., CASSONNET, P., RECTOR, A., DESAINTE, C., VAN WAEREBEEK, K., ALFARO-SHIGUETO, J., VAN RANST, M AND ORTH, G. (2007a) Genital warts in Burmeister's porpoises: characterization of *Phocoena spinipinnis* papillomavirus type 1 (PsPV-1) and evidence for a second, distantly related PSPV. *Journal of General Virology* 88: 1928-1933.

- VAN BRessem, M.-F., RAGA, A.J., BARRETT, T., SICILIANO, S., DI BENEDITTO, A.P., CRESPO, E. AND VAN WAEREBEEK, K. (2007b) A brief review of micro-parasites that may have a potential impact on the population dynamics of small cetaceans from South America. Paper SC/59/DW8 presented to the IWC Scientific Committee, May 2007 (unpublished).
- VAN WAEREBEEK, K. (1992) *Population identity and general biology of the dusky dolphin Lagenorhynchus obscurus (Gray, 1828) in the Southeast Pacific*. PhD Thesis, University of Amsterdam, The Netherlands. 76 pp.
- VAN WAEREBEEK, K. (1993) Geographic variation and sexual dimorphism in the skull of the dusky dolphin, *Lagenorhynchus obscurus* (Gray, 1828). *Fishery Bulletin* 91: 754-774.
- VAN WAEREBEEK, K., REYES, J.C., READ, A.J. AND MCKINNON, J.S. (1990) Preliminary observations of bottlenose dolphins from the Pacific coast of South America. Pages 143-154. *in* Leatherwood, S. and Reeves, R.R. (Eds). *The Bottlenose Dolphin*. Academic Press, San Diego, CA, USA.
- VAN WAEREBEEK, K., BAKER, A.N., FÉLIX, F., GEDAMKE, J., INÍGUEZ, M., SANINO, G.P., SECCHI, E., SUTARIA, D., VAN HELDEN, A. AND WANG, Y. (2007) Vessel collisions with small cetaceans worldwide and with large whales in the Southern Hemisphere, an initial assessment. *Latin American Journal of Aquatic Mammals* 6(1): 43-69 (this volume).
- VILANI-MORENO, F.R., LAURIS, J.R. AND OPROMOLLA, D.V. (2005) Cytokine quantification in the supernatant of mononuclear cell cultures and in blood serum from patients with Jorge Lobo's disease. *Mycopathology* 158: 17-24.
- WELLS, R.S., IRVINE, A. B. AND SCOTT, M.D. (1980) The social ecology of inshore odontocetes. Pages 263-317 *in* Herman, L.M. (Ed). *Cetacean Behavior: Mechanisms and Functions*. John Wiley and Sons, New York, NY, USA.
- WHO/UNICEF/WSSCC. (2001) *Global Water Supply and Sanitation Assessment 2001*. Report World Health Organization and United Nations Children's Found.
- WÜRSIG, B. AND JEFFERSON, R.A. (1990) Methods of photo-identification for small cetaceans. *Report of the International Whaling Commission* (special issue 12): 42-43.

Received 3 February 2007. Accepted 30 March 2007.